Ente Ospedaliero Cantonale

Ulcere cutanee neoplastiche e non: come curarle

Sally Imhof

GIOTI – 17 novembre 2022

Contenuto

- Patofisiologia ed eziologia della ferita cronica
- Ferite oncologiche
- Casi clinici

Guarigione secondaria della ferita

- Nessuna sutura
- Profondità/bordi ampi e frastagliati/difetto cutaneo
- Riempimento dal fondo non dal bordo
- Naturale processo di cicatrizzazione
- Ogni ferita a guarigione secondaria è contaminata con batteri.

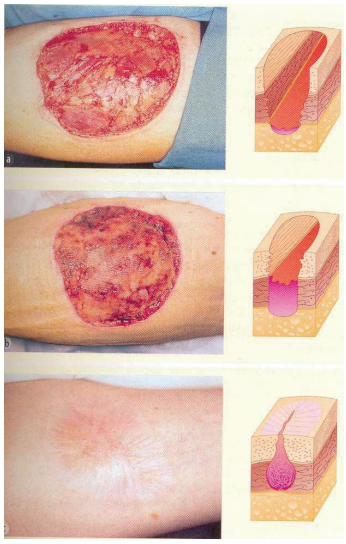

Cosa fare con una ferita cronica

1. Considerare i fattori che influenzano la cicatrizzazione
2. Valutare la vecchia medicazione
3. Riconoscere la fase di cicatrizzazione
4. Eseguire una pulizia (débridement) della ferita
5. Ispezionare la ferita, i bordi e il perilesionale

Fattori che influenzano la cicatrizzazione

- Età
- Nutrizione
- Patologie vascolari (IVC, arteriopatia, linfopatie)
- Patologie associate (DM, ITA, IRC, malattie endocrinologiche / ematologiche / neurologiche
- Stato immunologico
- Stato psichico
- Mobilità
- …

La veccchia medicazione

La medicazione che si rimuove ci da sempre tante informazioni sullo stato della ferita:

Ad esempio:

- **Colore** (sangue, fibrina, Pseudomonas)
- **Odore** (malodorante, nessun odore particolare)
- **Grado/quantità** dell‘essudato (bagnato, umido, secco, direzione)

Fasi di cicatrizzazione

- Fase **essudativa** (infiammatoria) 1- 4 gg
- Fase della **granulazione** (proliferazione cellulare) 2-14 gg
- **Epitelizzazione** (rimodellamento del tessuto cicatriziale) 3-21 gg

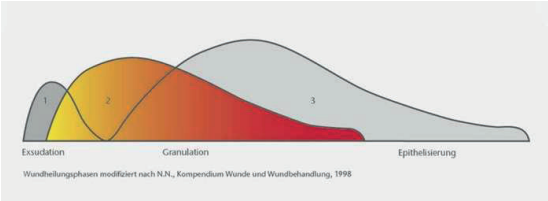

Nelle ferite croniche quste tempistiche non sono reali

Pulizia (débridement) della ferita

Scopo:
- Rimuovere detriti cellulari, fibrina, essudato, biofilm

Come fare?
- Bagnare una garza con abbondante soluzione (NaCl 0,9%/Ringer/Prontosan)
- Lasciarla agire per 10-15 minuti
- Eseguire il débridement della ferita con garze, batuffoli, pinzetta, curette o bisturi a scelta
- Dopo la pulizia passare alla fase asciutta tamponando con una garza asciutta

Ispezione della ferita, bordi e perilesionale

Valutazione ferita:

- Stadio
- Misura/profondità
- Grado di essudazione
- Odore (batteriologia)
- Tasche/fistole

Valutazione bordo e perilesionale:

- Intatto, senza irritazioni
- Arrossato
- Infiammato/caldo
- Macerato (troppo umido)
- Edematoso
- Secco, squamoso
- Presenza di fiacche/ flitteni
- Sottominato con tasche, tunnel, cavità

Cause di ferita cronica

Insufficienza venosa
- Primaria, secondaria (post-trombotica)
- Atrofia bianca

Arteriopatia periferica
- Ipertensione arteriosa
- Angiodermite necrotica (Ulcera di Martorell)
- Arteriopatie obliteranti
- Embolie arteriose
- Embolie di cristalli di colesterina
- Fistole artero-venose

90%

Vasculiti
- Primitive: atrofia bianca, periarterite nodosa...
- Secondarie: connettiviti (sclerodermia, poliartrite reumatoide...)

Infezioni ed infestazioni
- Ectima
- Erisipela, fasceite necrotica
- Pasteurella multocida
- Osteomielite
- Ulcera tropicale
- Microbatteriosi (atipici, tubercolosi, lepra)
- Sifilide
- Micosi superficiali e profonde (micetoma, nocardiosi,..)
- Parassitosi (leishmaniosi, dracontiasi, filariosi, miasi,...)
- Embolie settiche

Esogena
- Morsi, punture d'insetto
- Fisici (post-ematoma, decubito)
- Chimici (farmaci: citostatici, ...) o termici (crioterapia)
- Patomimia

Tumori
- Epiteliomi (carcinoma baso- e spinocellulare)
- Melanoma maligno
- Sarcoma di Kaposi, emangiosarcoma
- Micosi fungoide (linfoma),...

Affezioni dermatologiche
- Pioderma gangrenoso
- Eritema nodoso o eritema indurato di Bazin
- Lichen ruber planus erosivo
- Malattie bollose auto-immuni
- Pannicolite su adiponecrosi cutanea nodulare d'origine pancreatica
- Pannicolite di weber-Christian
- Sarcoidosi
- Radiodermite
- Geloni, alogenidi, amiloidosi secondaria,...

Emopatie
- Disturbi fibrinolisi (antitrombina III, proteina C, S, fattore XII, ...)
- Crioglobulinemie
- Trombocitosi (essenziale)
- Policitemia, leucemia
- Anemie (emolitica-cronica, falciforme, sideroblastica, ...)
- Drepanocitosi, ...

Altre
- Diabete mellito (bollosi agli arti inferiori, necrobiosi lipoidica)
- Iperparatiroidismo secondario
- Carenza di prolidasi
- Anomalie cromosomiche (Klinefelter)
- Progeria, gotta, ...

Malus perforans (d'origine neurologica con differnti cause)

Mainetti C et al. *Tribuna Medica Ticinese* 2007;72:251-8.

Ferite oncologiche

Le ferite neoplastiche possono svilupparsi a causa della crescita del tumore primario nella pelle, a causa di metastasi o a causa dell'invasione cutanea da parte di tumori che emergono da livelli più profondi.

Le ferite maligne possono presentarsi come un'ulcera simile ad un cratere o come noduli in rilievo con un aspetto simile a un cavolfiore.

Conoscere l'obiettivo

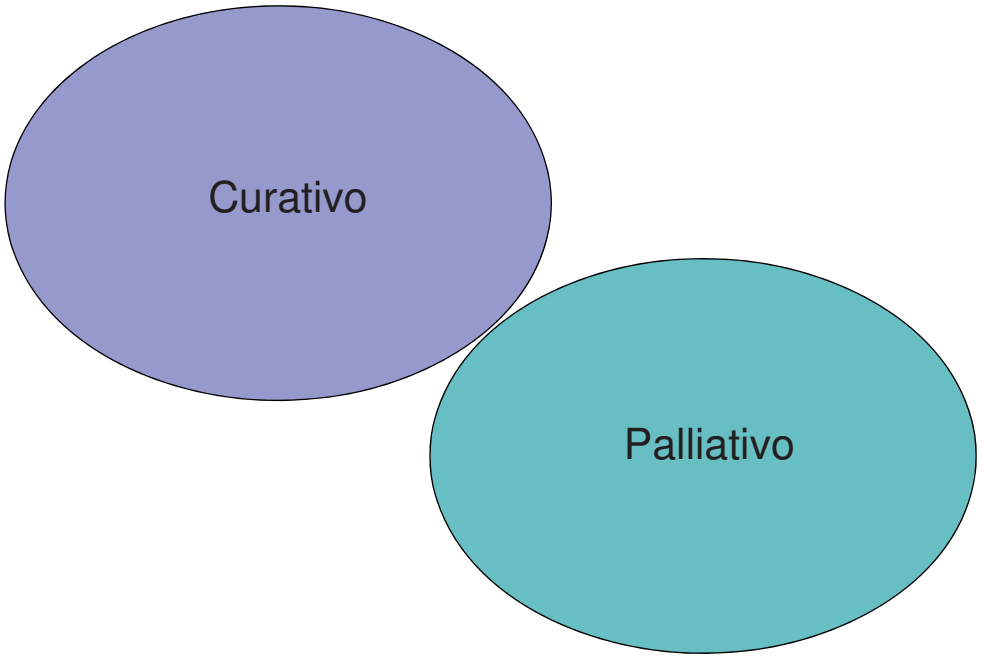

Qualità di vita

- La qualità della vita è spesso più importante per le persone con ferite incurabili
- Considerare il senso di benessere associato alla malattia
- Spostare la priorità dal “curativo” al “palliativo”
- Concentrarsi sulla riduzione della gravità dei **sintomi**

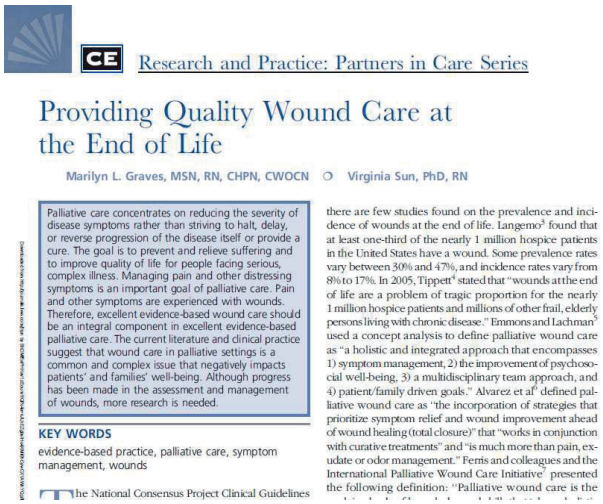

CE Research and Practice: Partners in Care Series

Providing Quality Wound Care at the End of Life

Marilyn L. Graves, MSN, RN, CHPN, CWOCN ○ Virginia Sun, PhD, RN

Palliative care concentrates on reducing the severity of disease symptoms rather than striving to halt, delay, or reverse progression of the disease itself or provide a cure. The goal is to prevent and relieve suffering and to improve quality of life for people facing serious, complex illness. Managing pain and other distressing symptoms is an important goal of palliative care. Pain and other symptoms are experienced with wounds. Therefore, excellent evidence-based wound care should be an integral component in excellent evidence-based palliative care. The current literature and clinical practice suggest that wound care in palliative settings is a common and complex issue that negatively impacts patients' and families' well-being. Although progress has been made in the assessment and management of wounds, more research is needed.

KEY WORDS
evidence-based practice, palliative care, symptom management, wounds

The National Consensus Project Clinical Guidelines

there are few studies found on the prevalence and incidence of wounds at the end of life. Langemo[3] found that at least one-third of the nearly 1 million hospice patients in the United States have a wound. Some prevalence rates vary between 30% and 47%, and incidence rates vary from 8% to 17%. In 2005, Tippett[4] stated that “wounds at the end of life are a problem of tragic proportion for the nearly 1 million hospice patients and millions of other frail, elderly persons living with chronic disease.” Emmons and Lachman[5] used a concept analysis to define palliative wound care as “a holistic and integrated approach that encompasses 1) symptom management, 2) the improvement of psychosocial well-being, 3) a multidisciplinary team approach, and 4) patient/family driven goals.” Alvarez et al[6] defined palliative wound care as “the incorporation of strategies that prioritize symptom relief and wound improvement ahead of wound healing (total closure)” that “works in conjunction with curative treatments” and “is much more than pain, exudate or odor management.” Ferris and colleagues and the International Palliative Wound Care Initiative[7] presented the following definition: “Palliative wound care is the

Graves, Marilyn L. MSN, RN, CHPN, CWOCN; Sun, Virginia PhD, RN Providing Quality Wound Care at the End of Life, Journal of Hospice & Palliative Nursing: April 2013 - Volume 15 - Issue 2 - p 66- 74 doi: 10.1097/NJH.0b013e31827edcf0

Dolore

- Sintomo più comune nei pazienti con ferite tumorali
- Associato ai cambi di medicazione

JOURNAL OF PALLIATIVE MEDICINE
Volume 23, Number 6, 2020
© Mary Ann Liebert, Inc.
DOI: 10.1089/jpm.2019.0617

Palliative Care Review
Feature Editor: Vyjeyanthi S. Periyakoil

Symptoms of Malignant Fungating Wounds and Functional Performance among Patients with Advanced Cancer: An Integrative Review from 2000 to 2019

Charles P. Tilley, MS, ANP-BC, ACHPN, CWOCN,[1,2] Mei R. Fu, PhD, RN, FAAN,[1,3] Janet Van Cleeve, PhD, MBA, RN,[1] Brooke Lee Crocilla, BSN,[4] and Christopher P. Comfort, MD[2]

Abstract

Introduction: Malignant fungating wounds (MFWs), non-healing wounds caused by aggressive proliferation of malignant tumors, afflict 5%–14.5% of patients with advanced cancer. We conducted an integrative review to evaluate the level of evidence of peer-reviewed literature published from 2000 to 2019 on symptoms of MFWs, and the impact of the symptoms on functional performance among patients with advanced cancer.
Methods: Four electronic databases were searched and 1506 articles were retrieved. A total of 1056 abstracts were screened for relevance and a full review of the 26 articles was performed. A total of 12 articles met inclusion criteria. An established quality assessment tool was used to rate the quality of the included studies.
Results: The overall quality of the included 12 studies was adequate. This integrative review of the literature provided strong evidence that patients with MFWs suffered multiple symptoms, including pain, odor, exudate, bleeding, pruritus, perceived wound status, perceived bulk effect and lymphedema. Quantitative research was not able to capture the occurrence and characteristics of all the identified symptoms. There was a lack of quantitative research on the impact of MFWs and symptoms on patients' functional performance. Yet, qualitative studies provided vivid description of how the symptoms negatively affected patients' functional performance. Future research should develop a clinical tool that enables the comprehensive assessment of symptoms of MFWs. Well-designed quantitative research is needed to delineate the impact of symptoms of MFWs on patients' functional performance to ensure quality palliative care.

Keywords: cancer; functional performance; malignant fungating wound; palliative; quality of life; wound symptoms

Tilley CP, Fu MR, Van Cleeve J, Crocilla BL, Comfort CP. Symptoms of Malignant Fungating Wounds and Functional Performance among Patients with Advanced Cancer: An Integrative Review from 2000 to 2019. J Palliat Med. 2020 Jun; 23(6):848-862. doi: 10.1089/jpm.2019.0617. Epub 2020 Apr 28. PMID: 32349622.

Dolore

- Sistemico
  - Trattamento del dolore nocicettivo e neuropatico
- Topico
  - Schiume con ibuprofene
  - Morfina (10 mg in 8 g di idrogel)
  - Olio di cannabis
  - Lidocaina
- Cura locale della ferita
  - Garze in silicone/cerotti in silicone
  - Protezione della cute perilesionale
  - Trattamento delle infezioni

Woo KY, Krasner DL, Kennedy B, Wardle D, Moir O. Palliative wound care management strategies for palliative patients and their circles of care. Adv Skin Wound Care. 2015 Mar;28(3):130-40; quiz 140-2. doi: 10.1097/01.ASW.0000461116.13218.43

Sanguinamento



134 Journal of Pain and Symptom Management Vol. 62 No. 1 July 2021

Brief Report

Frequency and Management of Hemorrhagic Malignant Wounds: A Retrospective, Single-Center, Observational Study

Marguerite Nicodème, NP, Sylvain Dureau, PharmD, Maxime Chéron, RN, Irène Kriegel, MD, Mélissandre Trenchand, eMaster, Pierre Bauër, PhD, and Isabelle Fromantin, RN, PhD

Research and Wound Care Unit (M.N., M.C., I.K., P.B., I.F), Institut Curie, Paris, France; Biostatistic Unit (S.D.), Institut Curie, Paris, France; Univ. Paris Est Créteil (P.B., I.F), INSERM, IMRB, CEpiA; and Master (M.T.), Cergy Paris University, CY Tech, Cergy, France

Check for updates

- Studio retrospettivo su 90 pazienti con ferite maligne
  - Sanguinamento nel 6% dei pazienti
  - Intensità sanguinamento spontaneo/indotto
    - Lieve 3-8%/47-60%
    - Moderato 5-10%/12-24%
    - Grave 0-11%/0–6%

Nicodème M, Dureau S, Chéron M, Kriegel I, Trenchand M, Bauër P, Fromantin I. Frequency and Management of Hemorrhagic Malignant Wounds: A Retrospective, Single-Center, Observational Study. J Pain Symptom Manage. 2021 Jul;62(1):134-140. doi: 10.1016/j.jpainsymman.2020.11.031. Epub

Sanguinamento

Category	Example	Comments
Natural haemostats	Calcium alginates Collagen Oxidized cellulose	Controls minor bleeds Available as a dressing materials Bioabsorbable
Coagulants	Gelatin sponge Thrombin	Risk of embolization
Sclerosing agents	Gelatin sponge Silver nitrate	May cause stinging and burning upon application Leaves a coagulum that can act as a pro-inflammatory stimulus
Fibrinolytic antagonists	Tranexamic acid	Oral agent Gastrointestinal adverse effects (nausea/vomiting)
Astringents	Alum solution Sucralfate	May leave a residue on wound
Vasoconstriction	Adrenaline	Gauze soaked in adrenaline 1:1000 applied with pressure for 10 minutes

Probst, S. Wound Care Nursing – A Person Centred Approch. 2021 Elsevier London

Essudato

- Medicazioni avanzate
  - super assorbenti
  - alginati
  - idrofibre
- Sacchetti per stomie
- Protezione dei bordi
- NPWT

OPEN

PRS GLOBAL OPEN VIEWPOINT

Negative Pressure Wound Therapy in Malignancy: Always an Absolute Contraindication?

Lacey R. Pflibsen, MD; Salvatore C. Lettieri, MD; Erwin A. Kruger, MD; Alanna M. Rebecca, MD, MBA; Chad M. Teven, MD

Sir,

Negative pressure wound therapy (NPWT) has increasingly been a part of the armamentarium of plastic surgeons because it reduces edema, improves angiogenesis, and promotes granulation formation in a variety of settings. Historically, an absolute contraindication to the use of NPWT is active malignancy due to theoretical risks of increased tumorigenesis, cancer spread, and hemorrhage.[1] However, few studies have evaluated the effects of NPWT on malignant wounds. In contrast, there is evidence that NPWT is beneficial for palliation in malignancy.[1–5]

Recently, we treated a 30-year-old female patient with a massive perivascular epithelioid cell neoplasm of the paraspinal musculature and lumbosacral spine with metastatic wounds.[4] Further, Makler et al[5] used NPWT to promote ingrowth of a dermal regeneration template in a previously irradiated and infected full-thickness calvarial wound from metastatic squamous cell carcinoma. At 6 weeks, there was significant integration of the dermal regeneration template, allowing for closure of the wound.

Indeed, several previous studies have demonstrated that NPWT may be of benefit in malignancy settings when used with a palliative intent. In patients at the end of life, measures that reduce pain, malodor, drainage of wounds, and limit trips to the operating room may improve quality of life. Further, although studies are limited and are not necessarily assessing for this, NPWT application

Downloaded from http://journals.lww.com/prsgo by BhDMf5ePHKav1zEoum1tQfN4a+kJLhEZgbsIHo4XMi0hCywCX1AWnYQp/IlQrHD3i3D0OdRyi7TvSFl4Cf3VC4/OAVpDDa8KKGKV0Ymy+78=on 08/24/2020

Pflibsen, Lacey R. MD; Lettieri, Salvatore C. MD; Kruger, Erwin A. MD; Rebecca, Alanna M. MD, MBA; Teven, Chad M. MD Negative Pressure Wound Therapy in Malignancy: Always an Absolute Contraindication?, Plastic and Reconstructive Surgery - Global Open: August 2020 - Volume 8 - Issue 8 - p e3007 doi: 10.1097/GOX.0000000000003007

Odore

- 11.9% dei pazienti con ferita tumorale
- Intensità
  - Lieve 27-50%
  - Moderato 25-34%
  - Forte 0-8%

206 Journal of Pain and Symptom Management Vol. 37 No. 2 February 2009

Original Article

Symptoms Associated with Malignant Wounds: A Prospective Case Series

Vincent Maida, MD, BSc, CCFP, ABHPM, Marguerite Ennis, PhD, Craig Kuziemsky, PhD, and Linda Trozzolo, RN
Division of Palliative Medicine (V.M.), University of Toronto, and Centre for Palliative Care (V.M., L.T.), William Osler Health Centre, Toronto; Applied Statistics (M.E.), University of Toronto, Toronto, and Telfer School of Management (C.K.), University of Ottawa, Ottawa, Canada

Maida V, Ennis M, Kuziemsky C, Trozzolo L. Symptoms associated with malignant wounds: a prospective case series. J Pain Symptom Manage. 2009;37(2):206-211. doi:10.1016/j.jpainsymman.2008.01.009

Odore

- Fase bagnata con: Metronidazol, Prontosan, ...
- Medicazioni con argento
- Carbone attivo sopra alla medicazione secondaria
- Caffé
- Sabbia per i gatti
- Assugrin della medicazione
- Schiuma da barba
- ...

Type of Dressing	Do you use any of the listed items?		Total (numbers who replied)	If yes to using the product(s), how effective to you consider them to be?		
	No *n* (%)	Yes *n* (%)		Not effective *n* (%)	Somewhat effective *n* (%)	Very effective n (%)
Activated charcoal - dressings	189(15.1)	1066 (85)	1255	31(2.9)	519(48.6)	516(48.4)
Topical metronidazole gel (Flaygl)	496(43.1)	655(57)	1151	85(12.9)	250(38.1)	320(49.8)
Alginate with silver – dressing	160(13.3)	1039(87)	1199	148(14.2)	651(62.6)	240(23.0)
Hydrofiber dressings with silver	218(18.8)	943(81)	1161	239(25.3)	531(56.3)	173(18.3)
Iodine based dressings	371(32.9)	757(67)	1128	228(30.1)	404(53.3)	125(16.5)
Foam with silver	283(24.7)	861(75)	1144	267(31.0)	479(55.6)	115(13.3)
Honey	609(53.8)	522(46)	1131	222(42.5)	218(41.7)	82(15.7)
Hydrogels	188(16.9)	923(83)	1111	709(76.3)	157(17.0)	57(6.1)
Alginate – dressing	145(12.9)	983(87)	1128	576(58.5)	352(35.8)	55(5.5)
Hydrocolloid dressings	275(24.6)	842(75)	1117	669(79.4)	129(15.3)	44(5.2)
Hydrofiber dressings	244(22.2)	855(78)	1099	570(66.6)	245(28.6)	40(4.6)
Foam dressings	174(15.5)	949(85)	1123	700(73.7)	210(22.1)	39(4.1)
Foam dressing silicon	283(25.4)	832(75)	1115	588(70.6)	210(25.2)	34(4.0)
Transparent dressing	398(36.3)	699(64)	1097	604(86.4)	67(9.5)	28(4.0)
Gauze	380(34.1)	736(66)	1116	669(90.8)	51(6.9)	16(2.1)

Gethin G, Grocott P, Probst S, Clarke E. Current practice in the management of wound odour: an international survey. Int J Nurs Stud. 2014 Jun;51(6):865-74. doi: 10.1016/j.ijnurstu.2013.10.013. Epub 2013 Oct 25. PMID: 24238490.

Caso clinico 1

- F
- 84 anni
- Nota per:
  - ITA
  - Osteoporosi
  - Sindrome mielodisplastica
  - Linfoma cutaneo zona occipitale (2014) trattato con Rx terapia

Caso clinico 1

- Ferita presente da qualche settimana (visita il 24.03.2016)

A cosa pensate?/ Fareste qualche esame?

Caso clinico 1

Biopsia cutanea

Linfoma cutaneo diffuso a grandi cellule B

Terapia

- Radioterapia arti inferiori
  (dal 1° giugno 2016 poi diverse altre sedute per nuovi noduli)
- Terapie locali specifiche + débridement

19.08.2016

Caso clinico 1

Caso clinico 2

- F
- 82 anni
- Nota per:
  - Cardiopatia ipertensiva
- Ulcere croniche agli arti inferiori presenti da più di 5 anni

Caso clinico 2

A cosa pensate?

A: ad un ulcera cronica

B: a fare subito degli accertamenti

C: ad un débridement e a delle medicazioni avanzate per qualche settimane/mese poi ev. degli altri accertamenti

Quali accertamenti fareste?

A: striscio

B: radiografia

C: biopsia

Caso clinico 2

Biopsia cutanea:

Carcinoma basocellulare nodulare, ulcerato

Quale trattamento fareste?

A: escissione chirurgica ⇦

B: débridement + terapia a pressione negativa

C: trattamento con pomata antibiotica

Caso clinico 2

Terapia

- Escissione
- Pompa pressione negativa
- Trapianto tipo Thiersch

GRAZIE!

Bibliografia

- Mainetti C. et al. *Tribuna Medica Ticinese* 2007;72:251-8.
- Graves, Marilyn L. MSN, RN, CHPN, CWOCN; Sun, Virginia PhD, RN Providing Quality Wound Care at the End of Life, Journal of Hospice & Palliative Nursing: April 2013 - Volume 15 - Issue 2 - p 66- 74 doi: 10.1097/NJH.0b013e31827edcf0
- Tilley CP, Fu MR, Van Cleeve J, Crocilla BL, Comfort CP. Symptoms of Malignant Fungating Wounds and Functional Performance among Patients with Advanced Cancer: An Integrative Review from 2000 to 2019. J Palliat Med. 2020 Jun; 23(6):848-862. doi: 10.1089/jpm.2019.0617. Epub 2020 Apr 28. PMID: 32349622.
- Woo KY, Krasner DL, Kennedy B, Wardle D, Moir O. Palliative wound care management strategies for palliative patients and their circles of care. Adv Skin Wound Care. 2015 Mar;28(3):130-40; quiz 140-2. doi: 10.1097/01.ASW.0000461116.13218.43
- Nicodème M, Dureau S, Chéron M, Kriegel I, Trenchand M, Bauër P, Fromantin I. Frequency and Management of Hemorrhagic Malignant Wounds: A Retrospective, Single-Center, Observational Study. J Pain Symptom Manage. 2021 Jul;62(1):134-140. doi: 10.1016/j.jpainsymman.2020.11.031. Epub
- Probst, S. Wound Care Nursing – A Person Centred Approch. 2021 Elsevier London
- Pflibsen, Lacey R. MD; Lettieri, Salvatore C. MD; Kruger, Erwin A. MD; Rebecca, Alanna M. MD, MBA; Teven, Chad M. MD Negative Pressure Wound Therapy in Malignancy: Always an Absolute Contraindication?, Plastic and Reconstructive Surgery - Global Open: August 2020 - Volume 8 - Issue 8 - p e3007 doi: 10.1097/GOX.0000000000003007
- O'Neill, L., Nelson, Z., Ahmad, N., Fisher, A. H., Denton, A., Renzi, M., Jr, Fraimow, H. S., & Stanisce, L. (2022). Malignant Fungating Wounds of the Head and Neck: Management and Antibiotic Stewardship. OTO open, 6(1), 2473974X211073306. https://doi.org/10.1177/2473974X211073306