UPDATE MELANOMA

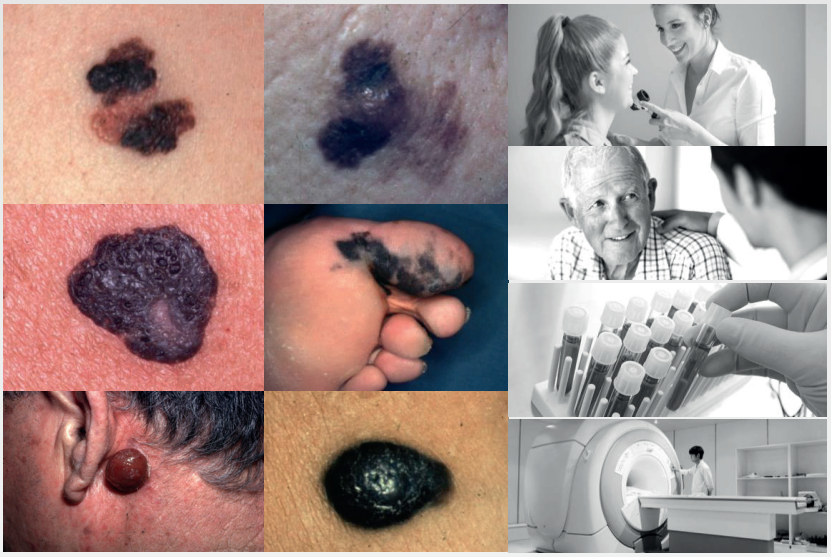

Cristina Mangas, M.D, Ph.D
Capo servizio di Dermatologia EOC
Medico IOSI
Responsabile CTCC
Cristina.mangas@eoc.ch

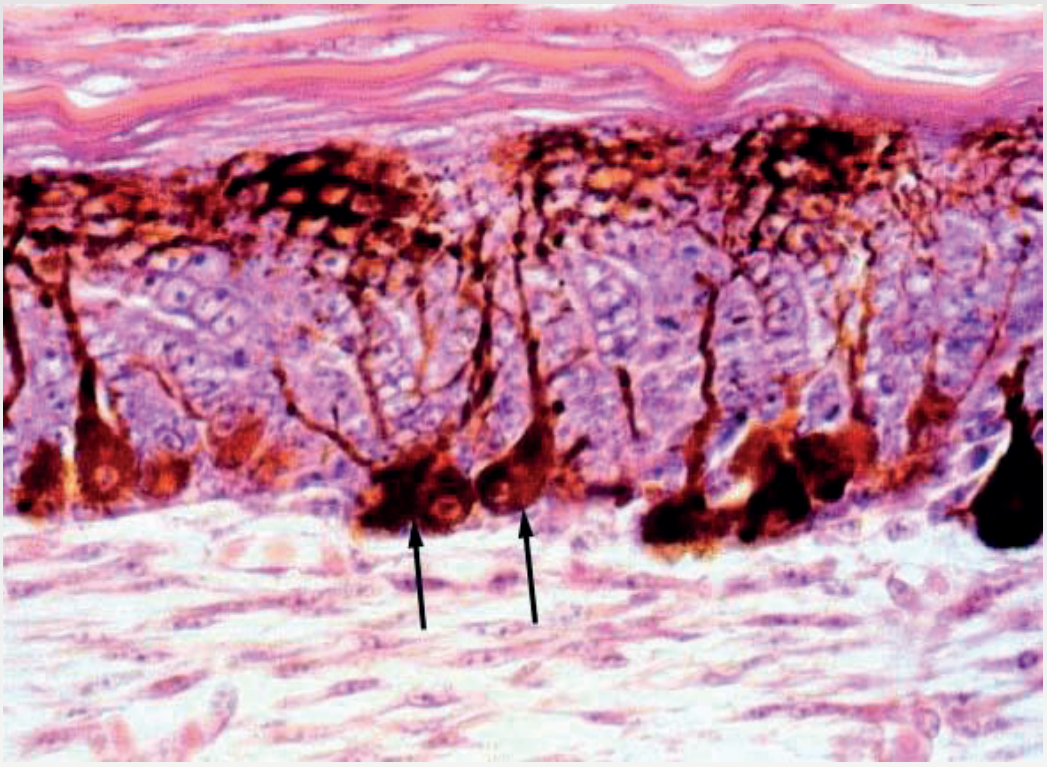

Benign Tumors: Melanocytic nevi

Melanocyte

Malignant Tumor Melanoma(MM)

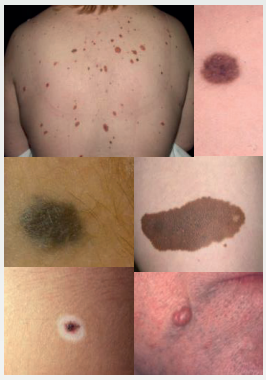

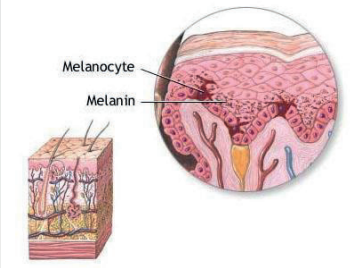

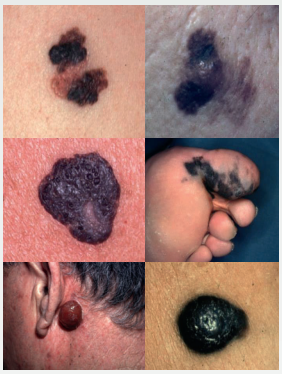

Uncertain behaviour neoplasms

(Atypical Spitz tumors)

Malignant Melanoma (MM)

Heterogeneous in etiopathogenesis, clinics and prognosis.

UV exposure

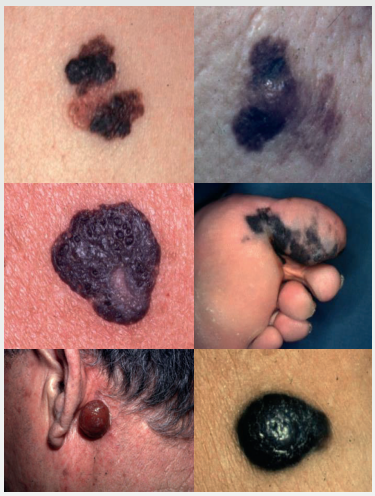

Genetic factors

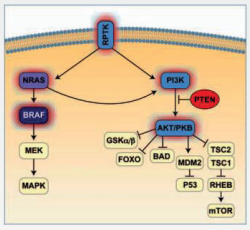

Primary tumor characteristics

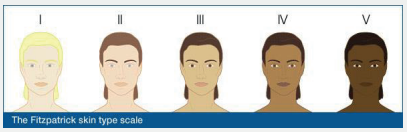

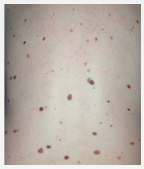

Patient features

PROGNOSIS

Malignant Melanoma epidemiology

Standarized incidence rate over the world
(x 100.000 hab./year)

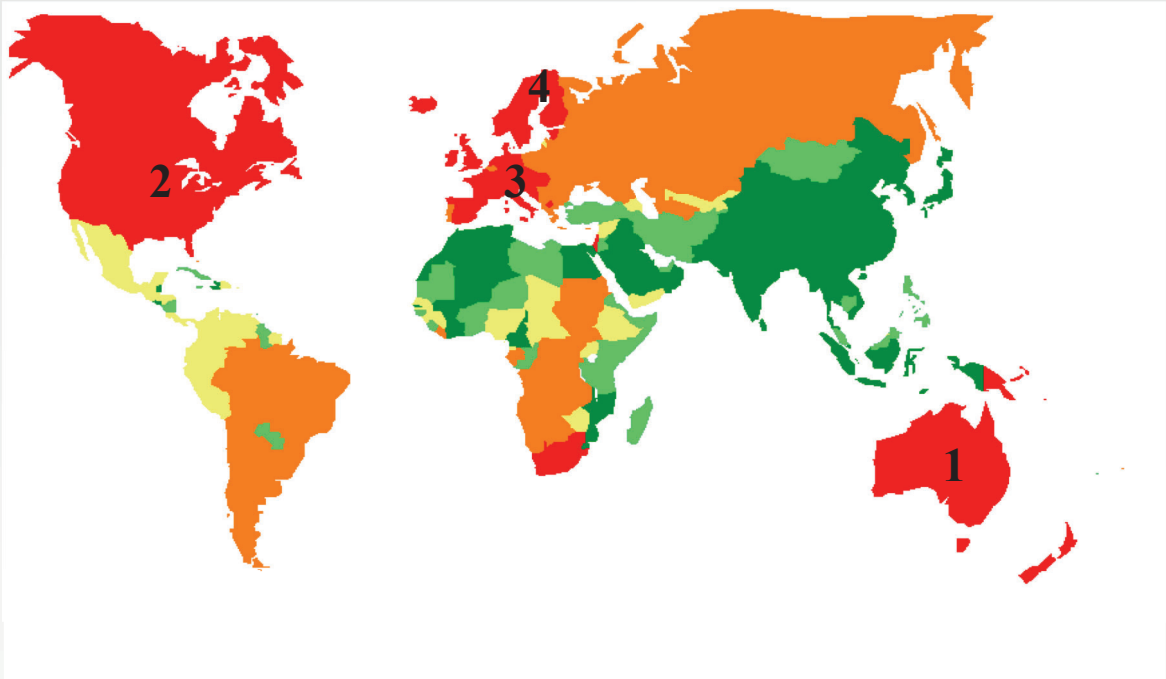

- Growing incidence and high morbimortality

http://eu-cancer.iarc.fr

FATTORI DI RISCHIO DI MM

Rischio Relativo di Melanoma
(Il rischio relativo indica il numero di volte in più di rischio di avere un MM rispetto alla popolazione generale)

Fattore di rischio	Rischio relativo approssimativo
Fototipo I-II (pelle chiara)	1.4
Numerose lentiggini	2.0 - 3.0
Occhi blu	1.6
Capelli rossi	2.4 - 4.0
Antecedenti di multiple scottature solare	2.0 - 3.0
≥ 6 nevus atipici	6.3
≥10 nevus displastici	12.0
> 100 nevus	3.1 - 16.5
Antecedente di MM	8.5

FATTORI DI RISCHIO DI MM

- Pazienti con rischio aumentato per lo sviluppo di MM:

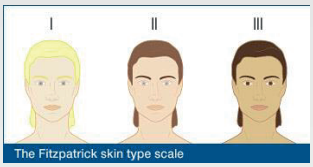

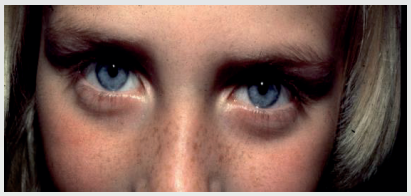

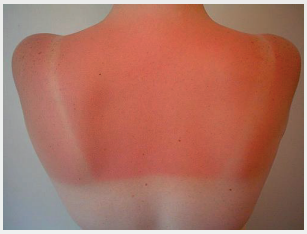



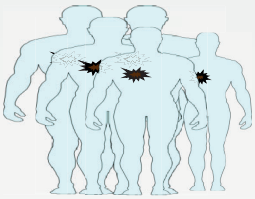

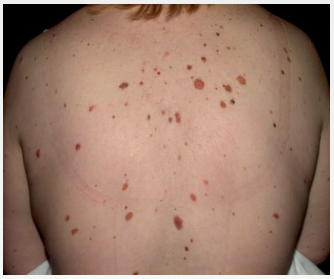

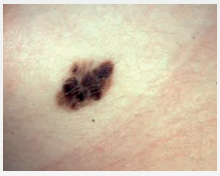

GENERAL DERMATOLOGY

BJD
British Journal of Dermatology

Genetic susceptibility to cutaneous melanoma in southern Switzerland: role of *CDKN2A*, *MC1R* and *MITF*

C. Mangas,[1] M. Potrony,[2,3] C. Mainetti,[1] E. Bianchi,[4] P. Carrozza Merlani,[5] A. Mancarella Eberhardt,[6] E. Maspoli-Postizzi,[4] G. Marazza,[1] A. Marcollo-Pini,[7] F. Pelloni,[4] C. Sessa,[8] B. Simona,[7] J.A. Puig-Butillé,[2,3,9] C. Badenas[2,3,9] and S. Puig[2,3]

[1]Dermatologia Ente Ospedaliero Cantonale (EOC) and [8]Istituto Oncologico della Svizzera Italiana (IOSI), Ospedale Regionale Bellinzona e Valli, Bellinzona, Switzerland
[2]Melanoma Unit, Hospital Clinic de Barcelona, Institut d'Investigacions Biomèdiques August Pi Sunyer (IDIBAPS), Universitat de Barcelona, Barcelona, Spain
[3]Centro de Investigación Biomédica en Red de Enfermedades Raras (CIBERER), ISCIII, Barcelona, Spain
[4]Private Dermatology Practice, Lugano, Switzerland
[5]Private Dermatology Practice, Bellinzona, Switzerland
[6]Private Dermatology Practice, Chiasso, Switzerland
[7]Private Dermatology Practice, Locarno, Switzerland

British Journal of Dermatology (2016)

What's already known about this topic?

- *CDKN2A* as a high-penetra
  mediate penetrance, are th
  bility.
- Mutation detection rates in
- *CDKN2A* mutation detectio
  at diagnosis and concomita

What does this study add?

- The genetic predisposition to melanoma in southern Switzerland is analysed for the first time.
- A CDKN2A high-risk mutation is detected in almost 10% of pedigrees and MITF p.E318K mutation in 7%.
- It is difficult to establish a rule for recommending genetic testing based on only the number of melanomas in the family or the individual.

Malignant Melanoma epidemiology

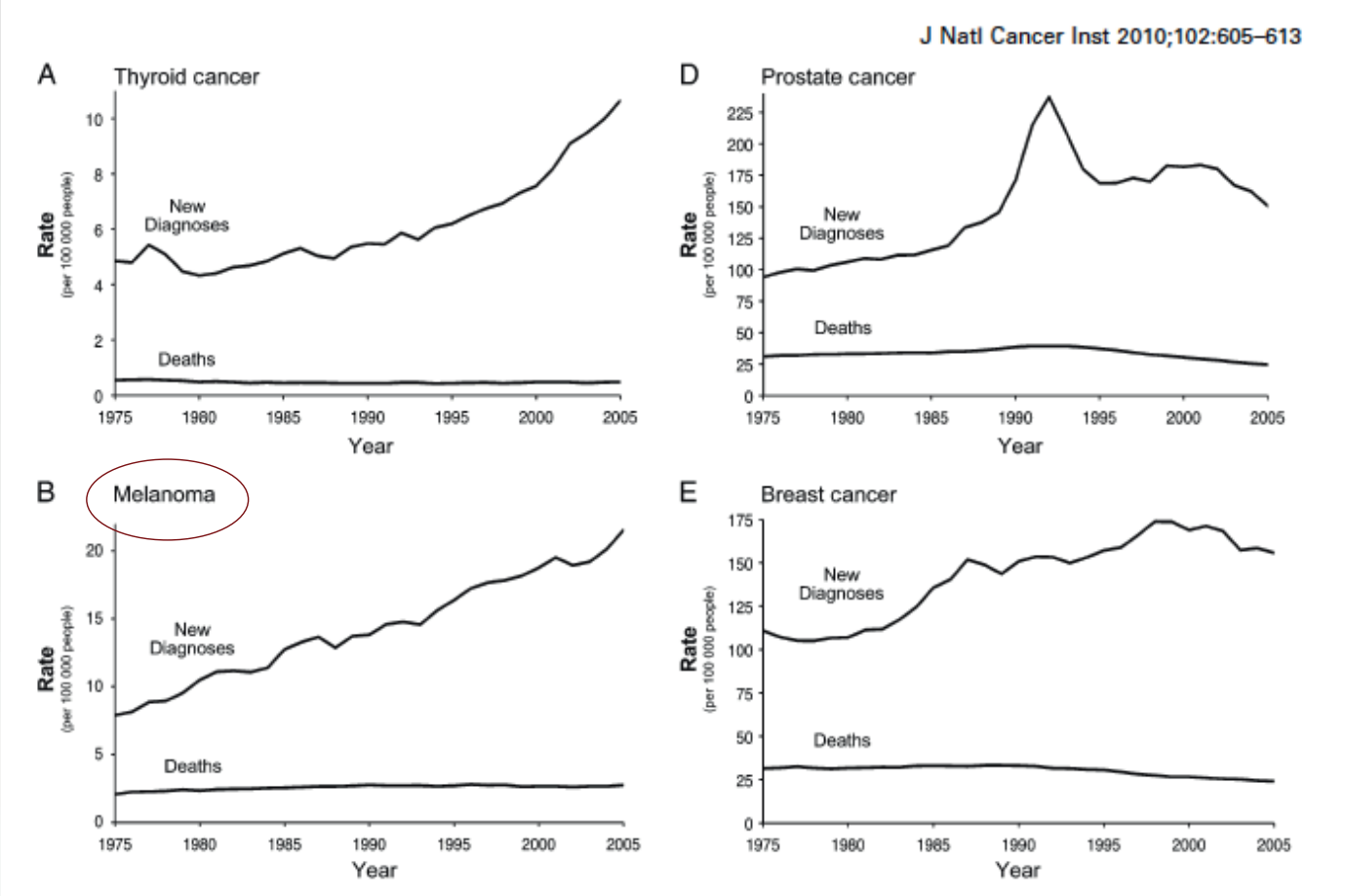

Malignant Melanoma epidemiology

EPIDEMIOLOGY AND HEALTH SERVICES RESEARCH

BJD British Journal of Dermatology

Melanoma epidemic: a midsummer night's dream?

N.J. Levell, C.C. Beattie,* S. Shuster and D.C. Greenberg*

Comparison of histological diagnosis, mortality and incidence of all lesions reported as melanomas in East Anglia between 1991 and 2004

Increased incidence was due to changes in the incidence of stage 1 disease, the combined incidence of more advanced stages being unchanged.

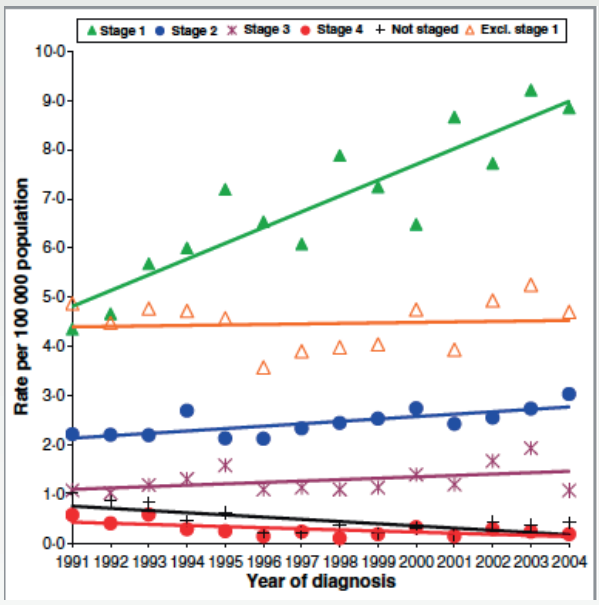

Malignant Melanoma diagnosis

Malignant Melanoma diagnosis

Manual dermoscopy

Digital dermoscopy

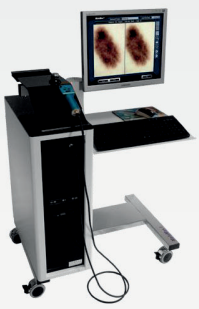

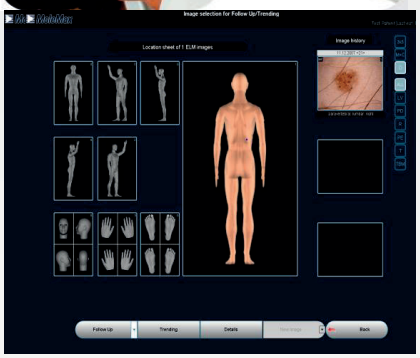

Malignant Melanoma diagnosis

Dermoscopy improves diagnostic accuracy compared to naked eye

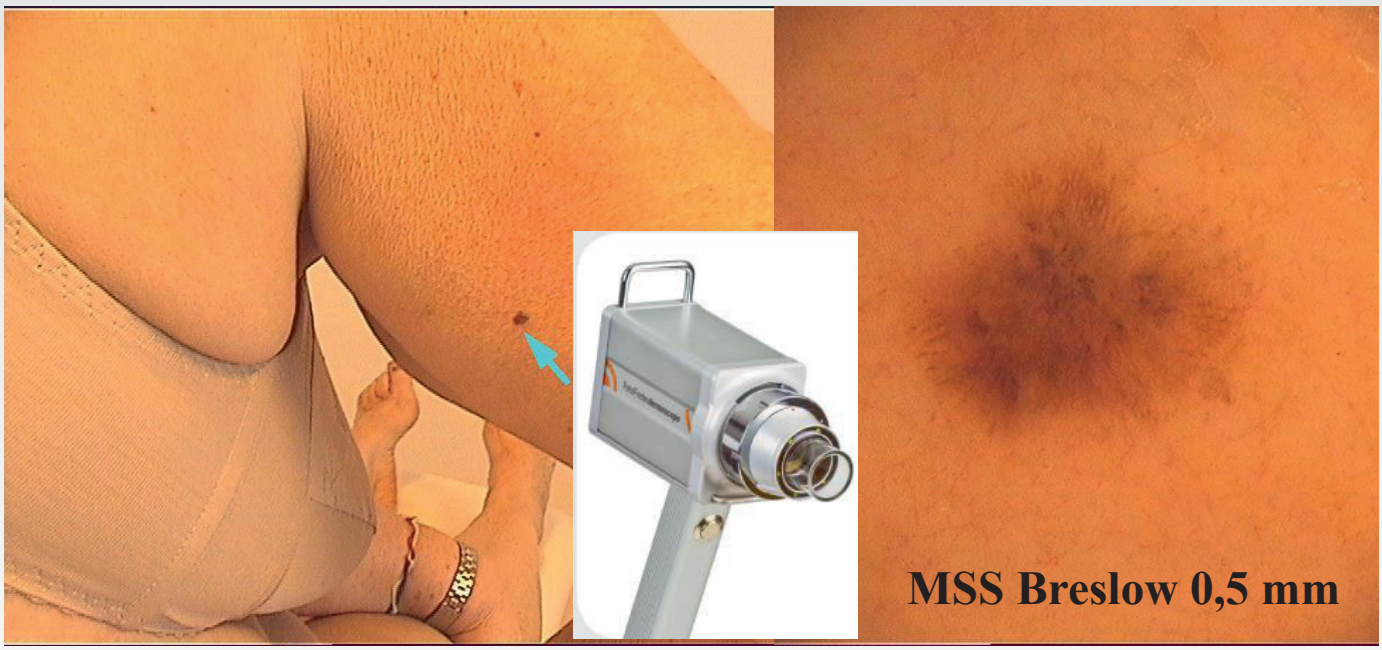

Argenziano G, et al. Accuracy in melanoma detection: A 10-year multicenter survey. J Am Acad Dermatol. 2011

Malignant Melanoma epidemiology

CLINICAL AND LABORATORY INVESTIGATIONS

BJD
British Journal of Dermatology

Slow-growing melanoma: a dermoscopy follow-up study

G. Argenziano, H. Kittler,* G. Ferrara,† P. Rubegni,‡ J. Malvehy,§ S. Puig,§ L. Cowell,¶ I. Stanganelli,** V. De Giorgi,†† L. Thomas,‡‡ P. Bahadoran,§§ S.W. Menzies,¶¶ D. Piccolo,*** A.A. Marghoob††† and I. Zalaudek‡‡‡

Conclusions This study provides evidence for the existence of a subgroup of slow-growing melanomas, which may explain the increase in the incidence of thin melanoma, despite stable rates of thick melanoma and melanoma-associated mortality.

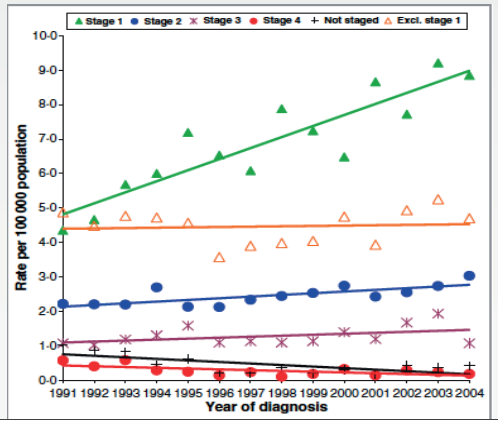



Selection of Patients for Long-term Surveillance With Digital Dermoscopy by Assessment of Melanoma Risk Factors. Haenssle et al.

Familial MM > Atypical Mole Sd> Personal Hx of MM

Long-term follow-up is required to allow the detection of slow-growing melanomas. In a population at high risk, digital follow-up should be maintained over time.

Short follow up (3-4 months) **Long follow up (6-12 months)**

N.F, 1969, healthy 50 years-old woman, single mom

- From May 2019: she observed a new, slow-growing, asymptomatic nodule in the abdominal skin with very fast growing and bleeding in the last two months.

But…she does not want to consult to the family doctor ”since she does not want to worry her 14 years-old son”.

- November 2019: She lost consciousness at home and a friend called the ambulance to go to the hospital (emergency room)

Emergency room: HYPOVOLEMIC HAEMORRAGIC SHOCK

- Laboratory tests and vital parameters

- TC total body (also cranial):
 No metastasi, no internal haemorragia

- General Status: Bleeding cutaneous tumor (15 cm of diameter) in abdominal zone

Value	Normal	Patient
Hemoglobin	120- 160 g/L	**24**
Erythrocits	4- 5,5 x10E12/L	**1,41**
Haematocrit	0,36-0,48 L/L	**0,10**
MCV	80- 100 fl	**68**
Microcytes	< 5 %	**23, 8**
Beats	60-80 bpm	**120**
Systolic T.A	120-140 mmHg	**104**
Dyastolic T.A	60-80 mmHg	**43**

First-line ipilimumab 3 mg/kg + nivolumab 1 mg/kg every 3 weeks for 4 doses

Two weeks after



Cycle 1 d1
- Blood tests OK
- No symptoms

- Symptoms: **tachycardia, asthenia, headache and thyroids goiter**

Value	Normal	Patient
TSH	0.27- 4,2 mU/L	**0,032**
FT3	3,1- 6,8 pmol/L	**33,2**
FT4	12- 22 pmol/L	**> 100**
Anti-TPO	< 60 U/mL	**5081**
Anti-Tireoglobulin	<33 U/mL	**4737**

Diagnosis: Hyperthiroidism (thyroroxicosis) immunomediate (imARs grade 3)

Patient is admitted to the hospital for diagnosis and treatment

Headache and seizures New MRI (one month after last one)

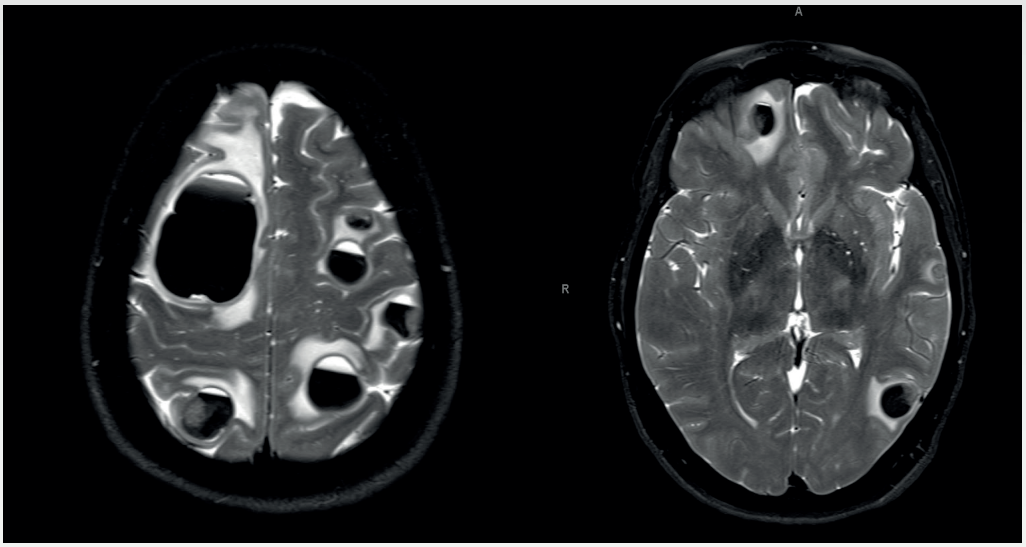

Patient died few days after due to cerebral progression of metastasis

Malignant Melanoma epidemiology

Prevalence of BRAF and NRAS mutations in fast-growing melanomas

Pigment Cell Melanoma Res. **26**; 429–431

Eduardo Nagore[1,2], Elke Hacker[3,4], Antonio Martorell-Calatayud[1], Víctor Traves[5], Carlos Guillen[1], Nicholas K. Hayward[3] and David Whiteman[6]

- Fast-growing melanomas (FGMs) increase in thickness by 0.5 millimeters or more per month (about one-fourth)
- FGMs have a worse prognosis and present mostly in elderly patients with fewer nevi and fewer freckles and at the trunk or acral sites
- Most are nodular subtype and with ulceration.
- Had a significantly higher frequency of mutations (NRAS/BRAF)

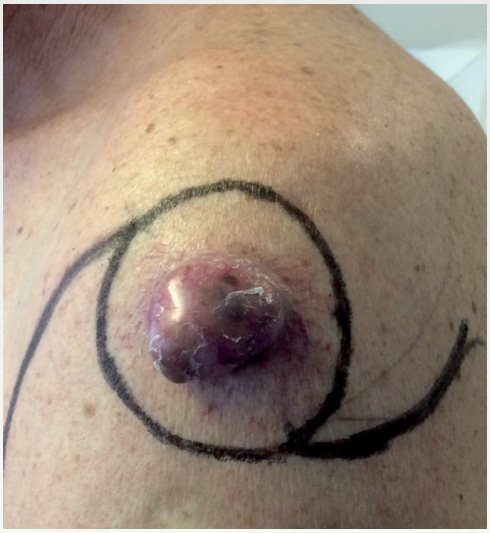

Malignant Melanoma epidemiology

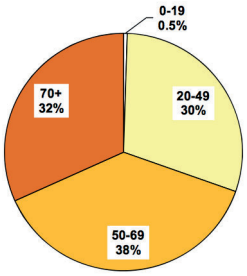

incidenza

Repubblica e Cantone Ticino

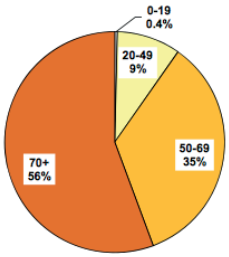

mortalità

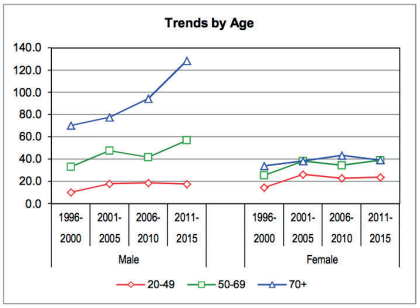

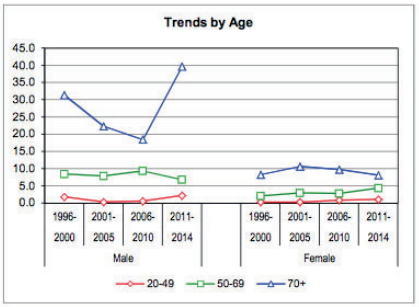

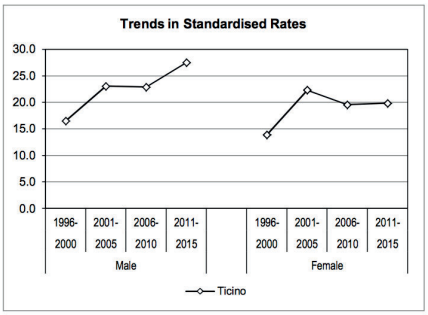

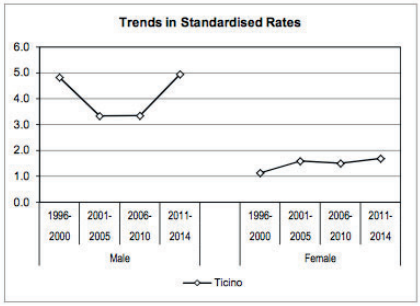

Malignant Melanoma epidemiology



J Natl Cancer Inst 2010;102:605–613

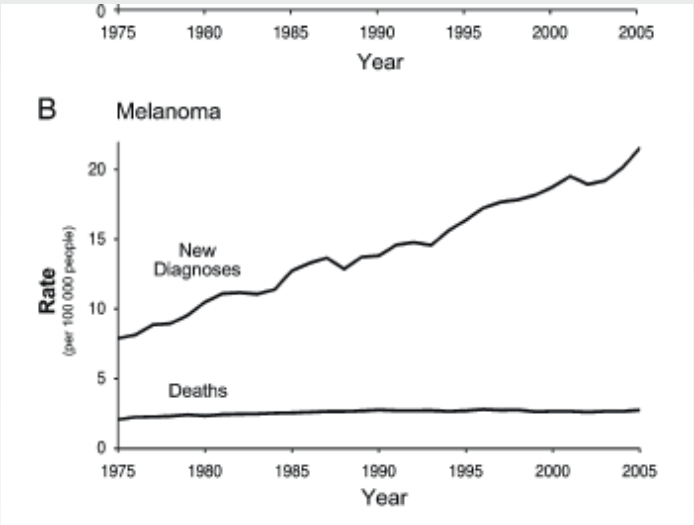

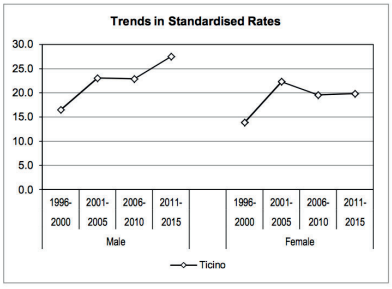

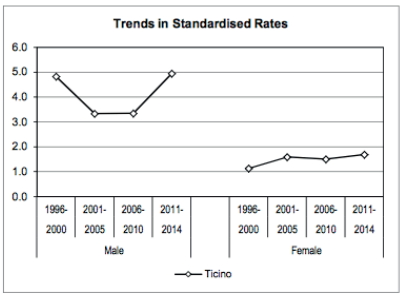

Superficial Spreading melanoma

- Most frequent type (70%)
- Average age of diagnosis: 40 years.
- > 50 moles and some of atypical features are associated risk factors.
- Repeated sunburn in childhood and adolescence is the most important environmental factor.
- The most frequent localization in the male is the back and in the female the legs.
- It starts with a flat phase that slowly changes in shape and color and grows (ABCD).

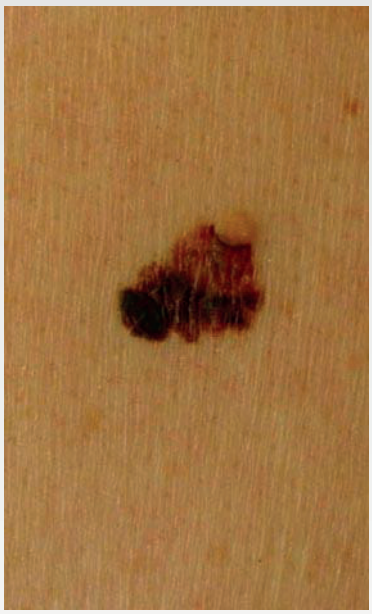

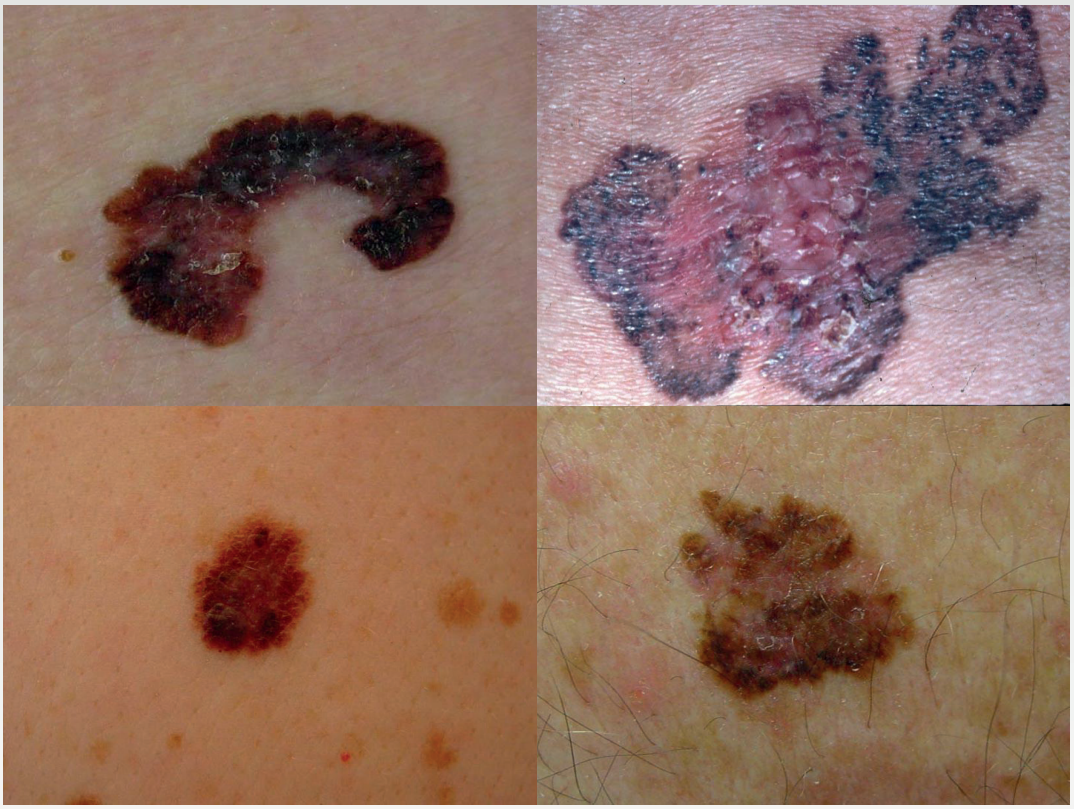

Nodular Melanoma

- 15% of the total of melanomas
- They are frequently older males
- Most common in the head and neck
- They are often symmetrical, exophytic or raised lesions, with a hard consistency and uniform color
- It does not follow the ABCD rule but the E.
- Ulceration and bleeding are frequent
- More aggressive type (deep MMs)
- It can also be non-pigmented, fast growing

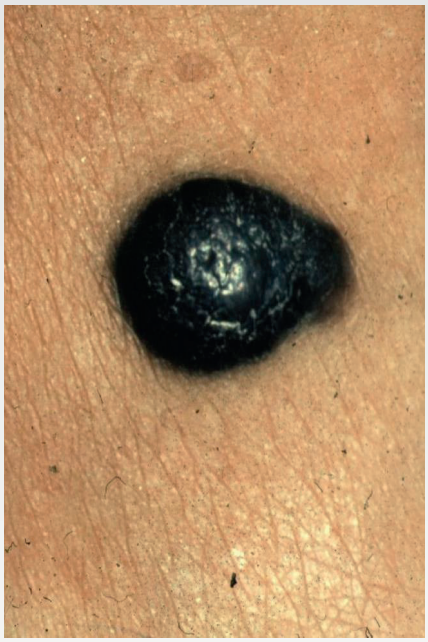

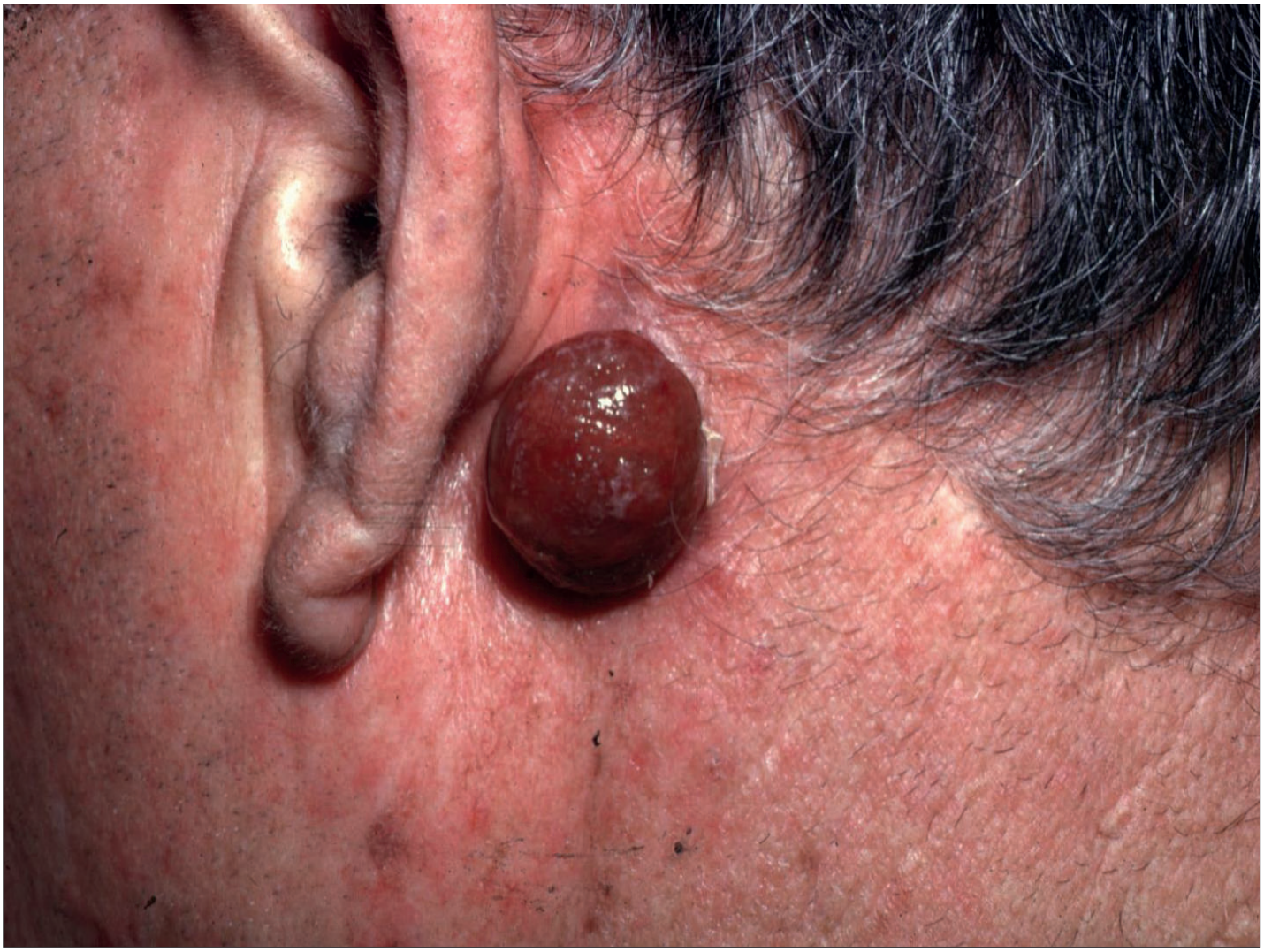

Lentigo Maligna (LM -in situ-) and Lentigo Maligna Melanoma (LMM –invasive-)

- 10-15% of the total of melanomas
- More frequent in elderly people with chronic actinic damage (outdoor workers)
- Much more common in the head and neck
- Pigmented plaque that grows very slowly

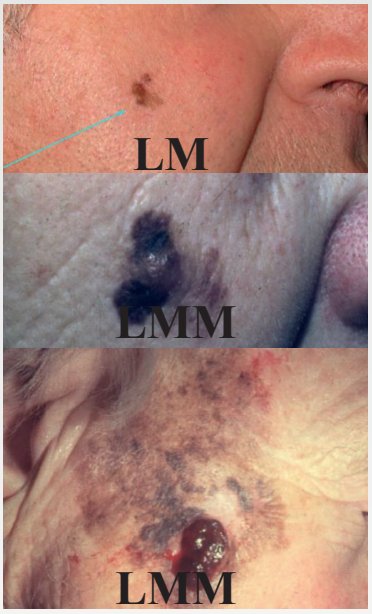

Lentiginous Acral Melanoma

- It represents 1-3% of MMs
- Acral skin of plants> palms
- More frequent in black or Asian skin
- It does not appear to be correlated with solar exposure
- The horizontal growth phase is similar to the SSM but the final thickness is greater
- Delay in diagnosis

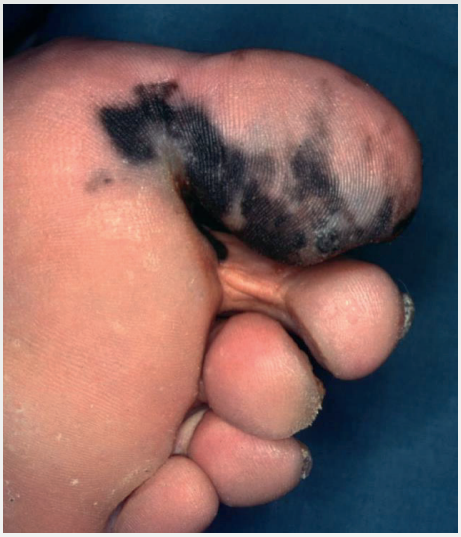

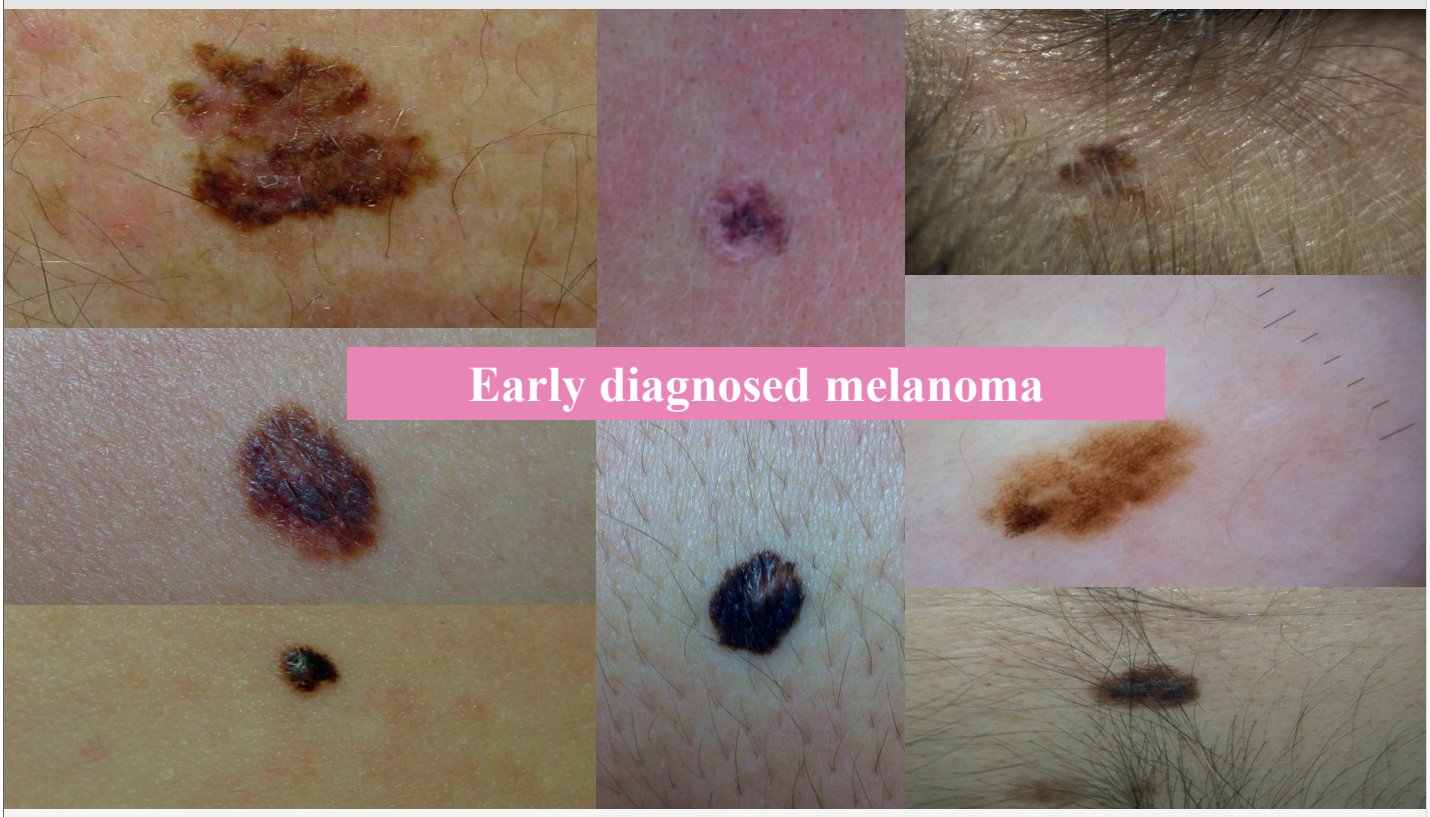
Early diagnosed melanoma

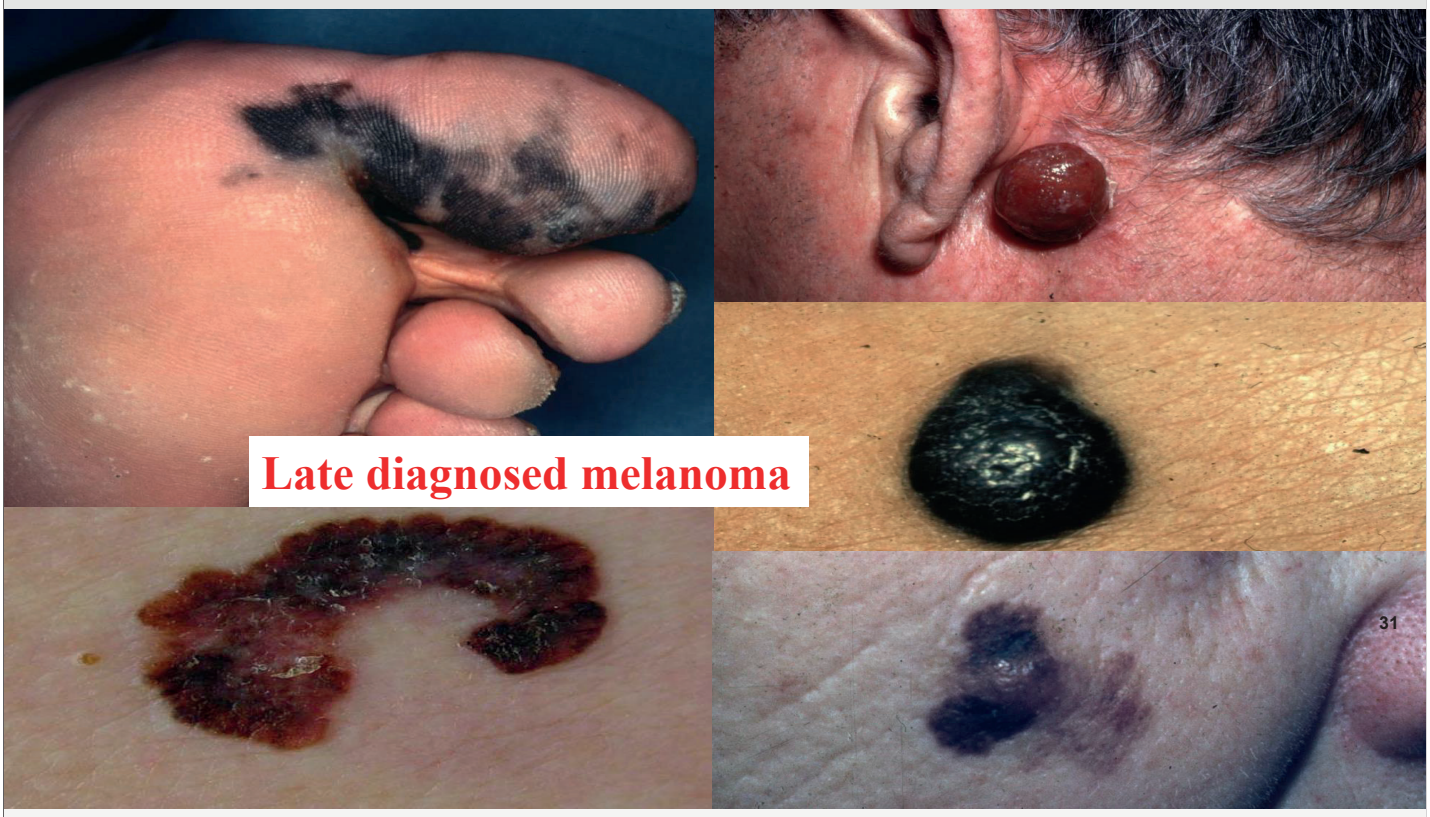
Late diagnosed melanoma

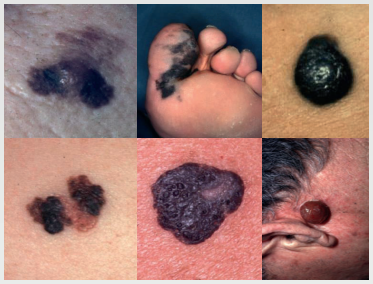

Clinical types of melanoma

↓

Pathological types of melanoma

↓

Molecular alterations

Clinical-Pathology-Molecular-**Biological** Melanoma Subtypes

UV intermittent

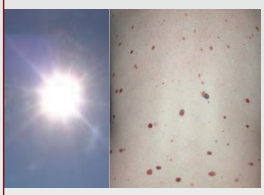

FAMMM

SSM/LMM

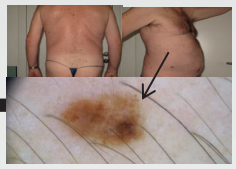

Slow growing

MM ex nevus/ SSM/ Pagetoide

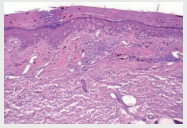

LOW mutations

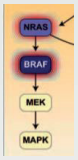

UV chronic



No FAMMM

Nodular

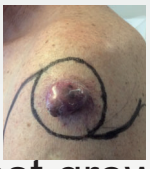

Fast growing

Nodular/SSM with Vertical phase

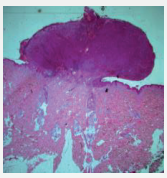

HIGH mutations

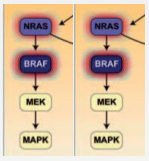

Pigment Cell Melanoma Res 2015; 26; 429–431

Type of UVR exposure/CSD	Subtype of melanoma	Affected genes
Low-CSD melanoma	SSM	BRAF V600 E/K or NRAS CDKN2A TP53 SWI/SNF TERT
High-CSD melanoma	LMM Desmoplastic melanoma	NF1, NRAS, BRAF, KIT CDKN2A TP53 SWI/SNF TERT
Low to no UVR exposure (or variable/ incidental)	Spitz melanoma	HRAS, ROS1, NTRK1, NTRK3, ALK, RET, MET, BRAF, CDKN2A, TERT
	Acral melanoma Mucosal melanoma (genital, oral, sinonasal)	NRAS, KIT, NF1, SPRED1, BRAF, CCND1, ALK, ROS1, RET, NTRK1, CDKN2A, CDK4, TP53, SWI/SNF, TERT
	Uveal melanoma	GNAQ, GNA11, CYSLTR2, PLCB4, BAP1, SF3B1, EIF1AX
	Melanoma arising in congenital naevus	NRAS
	Melanoma arising in blue naevus	GNAQ, GNA11, CYSLTR2, BAP1, SF3B1, EIF1AX

CSD = Cumulative sun damage.

Classification of melanomas (WHO 2018)

Including epidemiological, clinical, pathological, and common genomic features.

Skin screening present-future

- CNN using a dataset of 129,450 clinical images classify: SCC/SK/MN/MM
- Comparing with 21 board-certified dermatologists: competence comparable
- It is projected that 6.3 billion smartphone subscriptions will exist by the year
- Potentially provide low-cost universal access to vital diagnostic care.
- Health care by smartphones (230 apps)

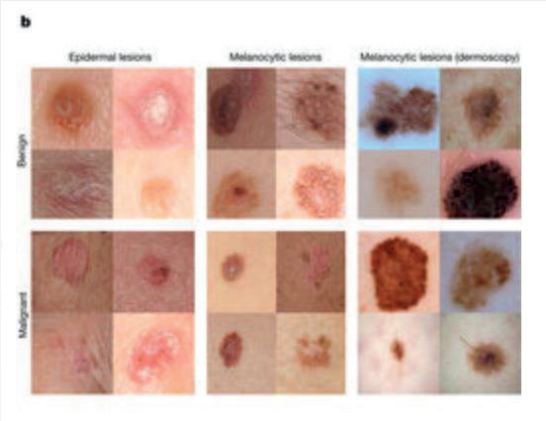

Esteva A. Nature 542, 115–118 (2017)

Mensaje de Mack Horton en Instagram / Instagram

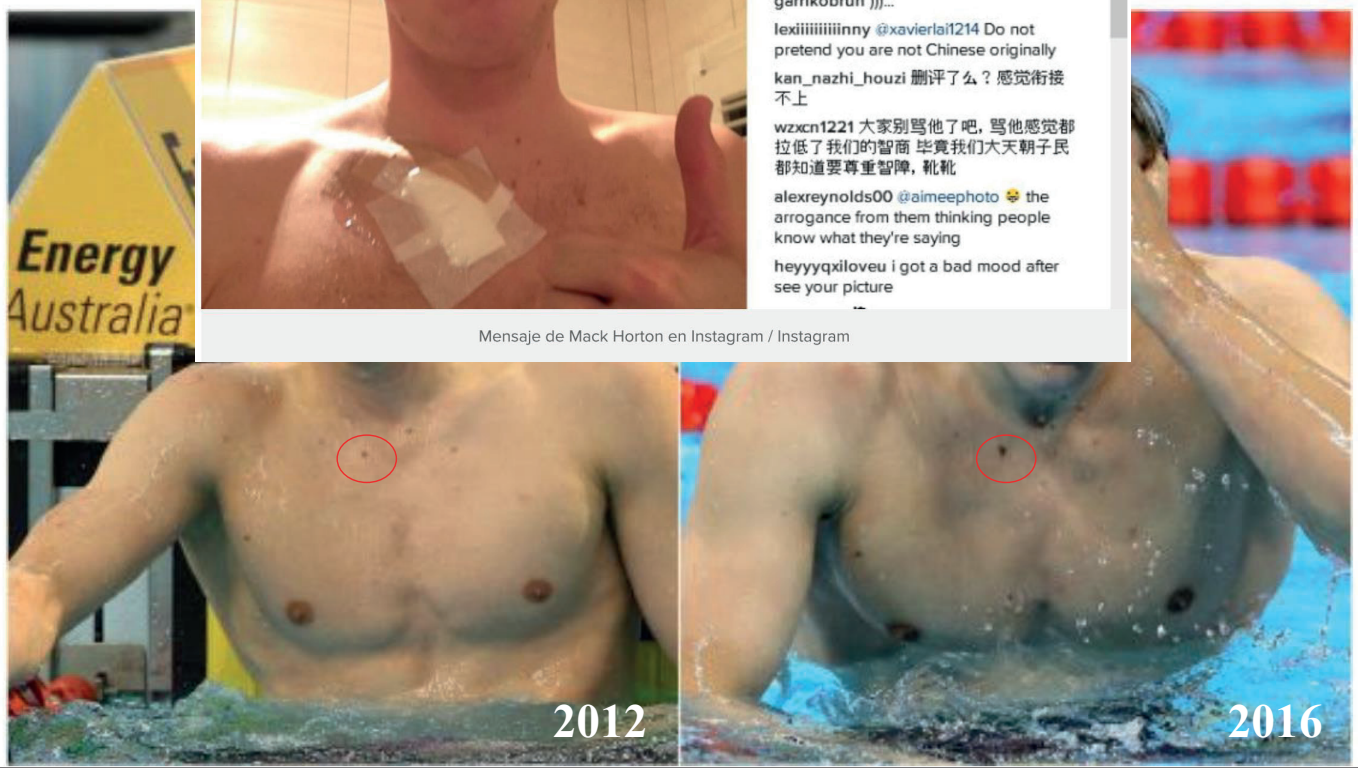

La presa a carico nel melanoma

Stadio I-II

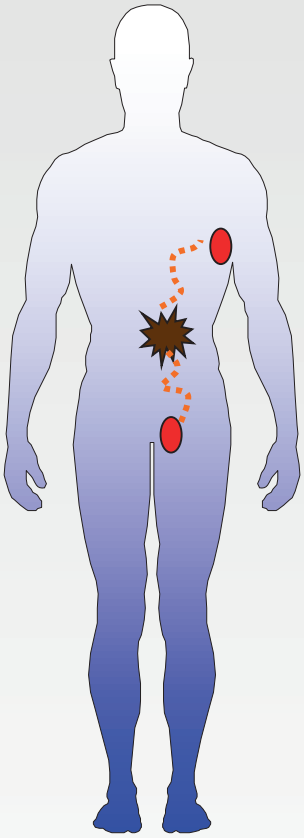

Stadio III

Stadio IV

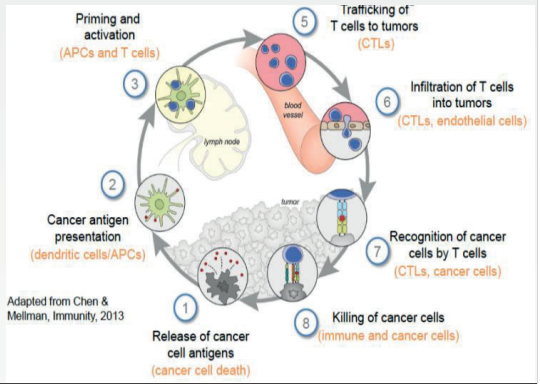

Radicalizzazioni margini nel melanoma

stage	Breslow	safety margin
IS	0	0.5 cm
pT1-T2	0.1 – 2.0 mm	1 cm
pT3-T4	>2.0	2 cm

Blaubuch IOSI, ESMO 2020 Guidelines, EORTC-EADO Guidelines

Annals of Oncology 30 (2019)
European Journal of Cancer 126 (2020)

Radicalizzazioni margini nel melanoma

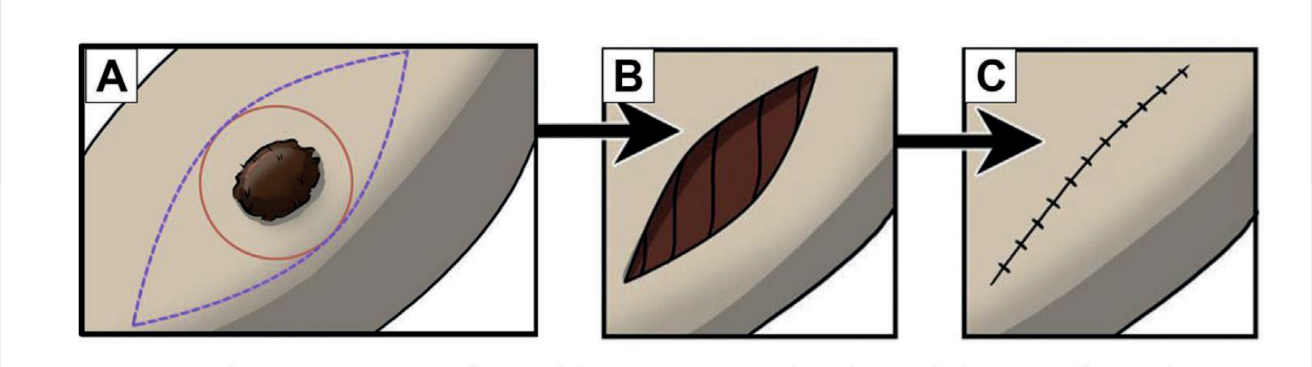

- L'escissione ampia con i margini raccomandati è la terapia definitiva dei melanomi cutanei primari
- La profondità dell'escissione per i melanomi invasivi dovrebbe essere al livello di fascia, ma non è necessario includerla.
- La chiusura di ampi diffetti può variare in base alle preferenze del chirurgo, ma bisogna considerare la ricorrenza locale, le future terapie e la limitazione della morbilità (p. es: viso, acrali, genitali).

Surg Clin N Am 100 (2020)

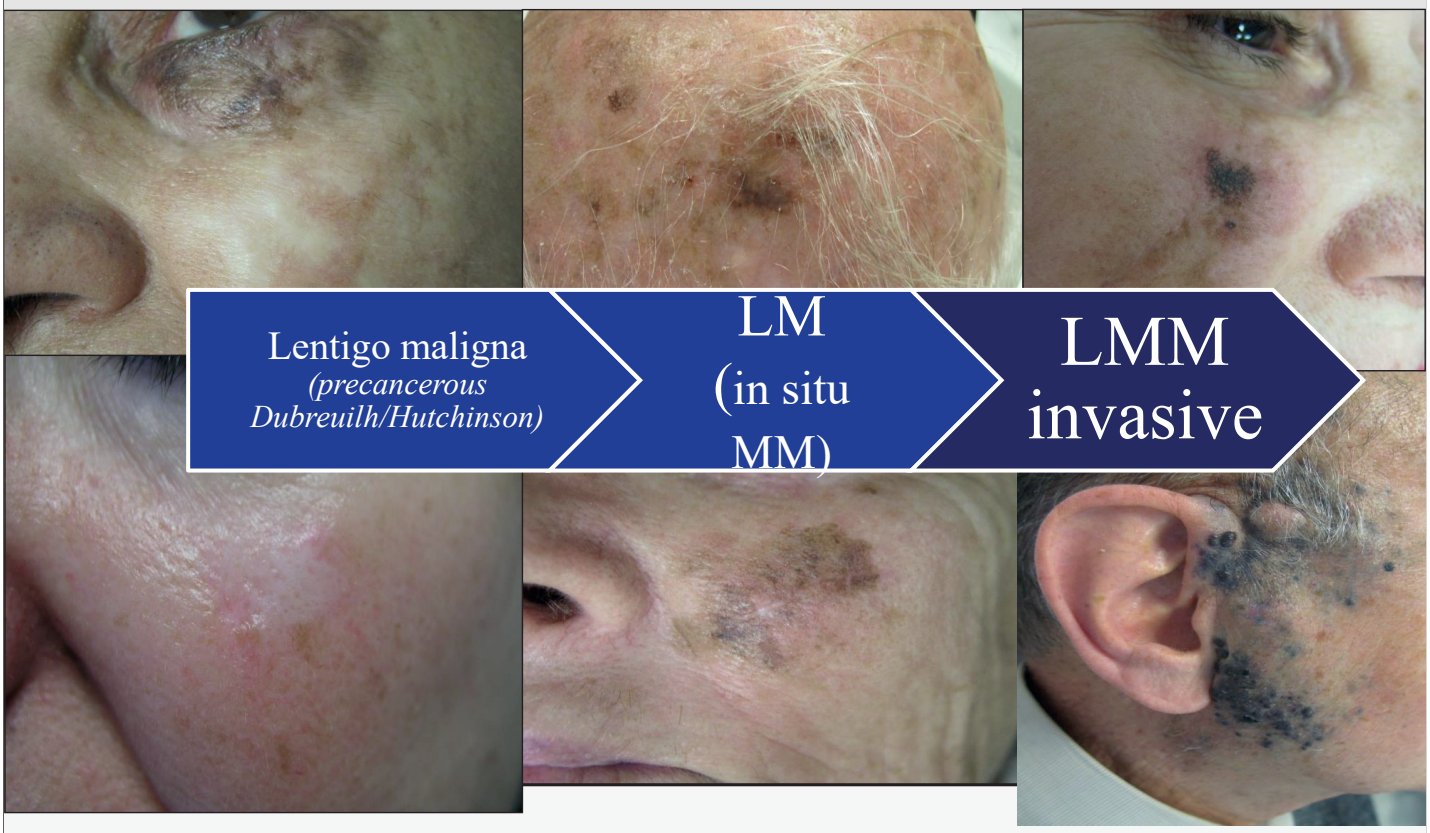
Lentigo maligna
(precancerous
Dubreuilh/Hutchinson)
LM
(in situ
MM)
LMM
invasive

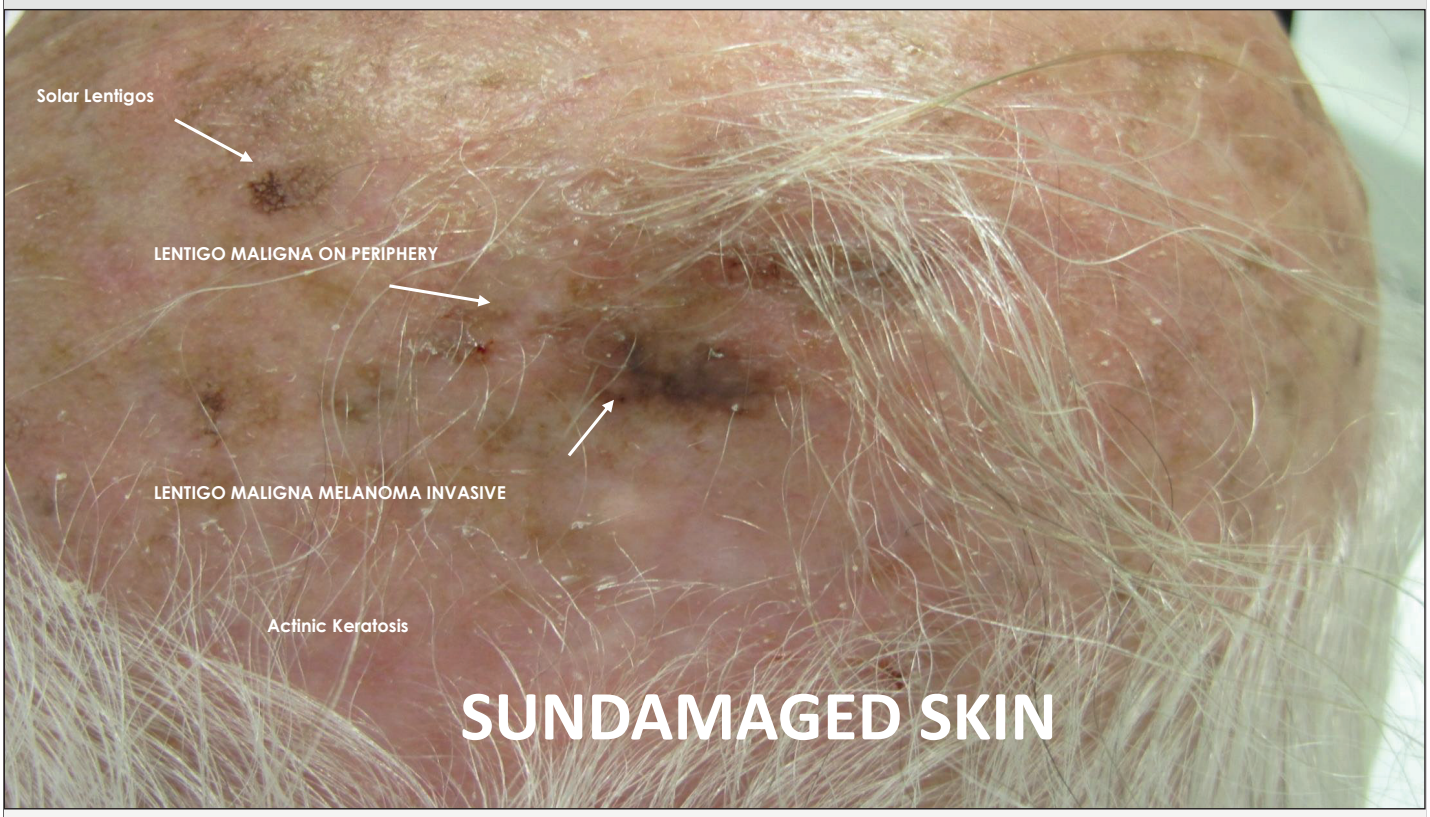
Solar Lentigos
LENTIGO MALIGNA ON PERIPHERY
LENTIGO MALIGNA MELANOMA INVASIVE
Actinic Keratosis
SUNDAMAGED SKIN

Non-Surgical treatments in LM

- Clearance range varies widely ≈55-90%
- Mean of recurrences according to one systematic review[1]:
  - Radiotherapy **11.5% recurrences** (1-96 months)[1]
  - Imiquimod cream **24.5%** (2-49 months)[1]
  - Laser therapy **34.4%** (8-78 months)[1]
  - Laser + imiquimod postlaser **23%** after 3years[2]
  - Criotherapy, Topical retinoids + imiquimod,…

[1]*Read et al. J Eur Acad Dermatol Venereol. 2016 May;30(5):748-53*
[2]Greveling et al. *Br J Dermatol 2016; 174:1134-36*

Prognostic factors in melanoma (8th AJCC 2017)

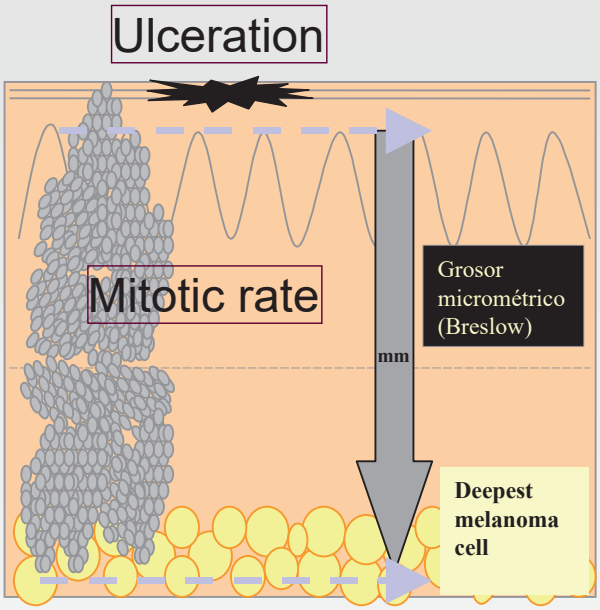

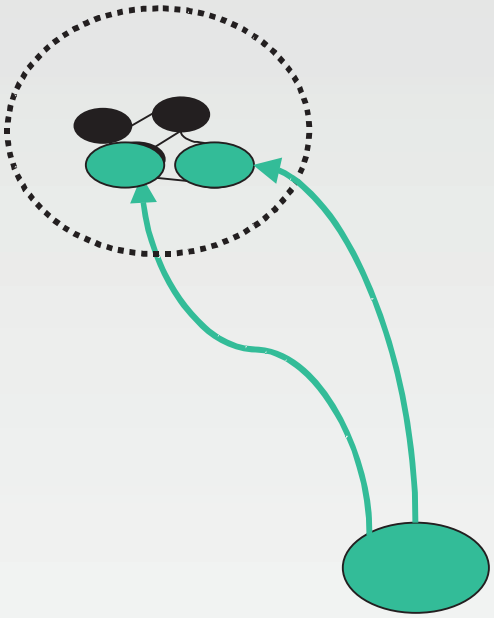

Thickness primary tumor

Nodal Status

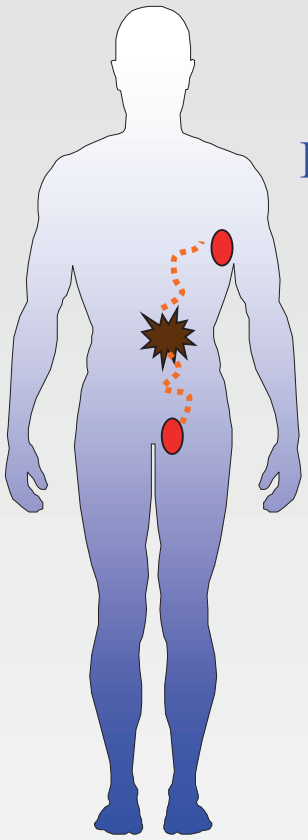

Indicazioni a BLS (lineaguida Blaubuch 2022

Stadio	Breslow	BLS
pT1a*	< 0.8 non ulcerato	Non indicata
pT1b	< 0.8 ulcerato o ≥ 0.8 e < 1.0 (T1b):	2022 INDICATA
≥ T2a	≥ 1.0 mm	

*In caso di altri fattori di rischio nel tumore primario (margini profondi coinvolti, alto indice mitotico, fase di crescita verticale): discutere BLS

8th AJCC 2017 Melanoma staging

T CATEGORY	THICKNESS	ULCERATION STATUS
TX: Primary tumor thickness cannot be assessed (eg, diagnosis by curettage)	Not applicable	Not applicable
T0: No evidence of primary tumor (eg, unknown primary or completely regressed melanoma)	Not applicable	Not applicable
Tis (melanoma in situ)	Not applicable	Not applicable
T1	≤1.0 mm	Unknown or unspecified
T1a	<0.8 mm	Without ulceration
T1b	<0.8 mm	With ulceration
	0.8-1.0 mm	With or without ulceration
T2	>1.0-2.0 mm	Unknown or unspecified
T2a	>1.0-2.0 mm	Without ulceration
T2b	>1.0-2.0 mm	With ulceration
T3	>2.0-4.0 mm	Unknown or unspecified
T3a	>2.0-4.0 mm	Without ulceration
T3b	>2.0-4.0 mm	With ulceration
T4	>4.0 mm	Unknown or unspecified
T4a	>4.0 mm	Without ulceration
T4b	>4.0 mm	With ulceration

Overall, SLN metastases are very infrequent (<5%) in melanomas<0.8 mm in thickness but occur in approximately 5% to 12% of patients with primary melanomas from 0.8 to 1.0 mm in thickness, and consensus guidelines have recommended that SLN biopsy be considered in this latter group of patients, particularly when other adverse prognostic parameters are also present

Gershenwald JE et al.
Melanoma staging: Evidence-based changes in the American Joint Committee on Cancer eighth edition cancer staging manual. CA Cancer J Clin. 2017 Oct

8th AJCC 2017 Melanoma staging

When T is...	And N is...	And M is...	Then the pathological stage group is...
Tis	N0	M0	0
T1a	N0	M0	IA
T1b	N0	M0	IA
T2a	N0	M0	IB
T2b	N0	M0	IIA
T3a	N0	M0	IIA
T3b	N0	M0	IIB
T4a	N0	M0	IIB
T4b	N0	M0	IIC
T0	N1b, N1c	M0	IIIB
T0	N2b, N2c, N3b, or N3c	M0	IIIC
T1a/b-T2a	N1a or N2a	M0	IIIA
T1a/b-T2a	N1b/c or N2b	M0	IIIB
T2b/T3a	N1a-N2b	M0	IIIB
T1a-T3a	N2c or N3a/b/c	M0	IIIC
T3b/T4a	Any N ≥N1	M0	IIIC
T4b	N1a-N2c	M0	IIIC
T4b	N3a/b/c	M0	IIID
Any T, Tis	Any N	M1	IV

Clinico-pathological status TNM:
For Stage III, you need T

8th AJCC 2017 Melanoma staging

AJCC Eighth Edition
Melanoma Stage III Subgroups

N Category	T Category								
	T0	T1a	T1b	T2a	T2b	T3a	T3b	T4a	T4b
N1a	N/A	A	A	A	B	B	C	C	C
N1b	B	B	B	B	B	B	C	C	C
N1c	B	B	B	B	B	B	C	C	C
N2a	N/A	A	A	A	B	B	C	C	C
N2b	C	B	B	B	B	B	C	C	C
N2c	C	C	C	C	C	C	C	C	C
N3a	N/A	C	C	C	C	C	C	C	D
N3b	C	C	C	C	C	C	C	C	D
N3c	C	C	C	C	C	C	C	C	D

Instructions
(1) Select patient's N category at left of chart.
(2) Select patient's T category at top of chart.
(3) Note letter at the intersection of T&N on grid.
(4) Determine patient's AJCC stage using legend.

N/A=Not assigned, please see manual for details.[4]

Legend

A	Stage IIIA
B	Stage IIIB
C	Stage IIIC
D	Stage IIID

Gershenwald JE
Melanoma staging: Evidence-based changes in the American Joint Committee on Cancer eighth edition cancer staging manual. CA Cancer J Clin. 2017 Oct

7th AJCC 2009/ 8th AJCC 2017 Melanoma staging

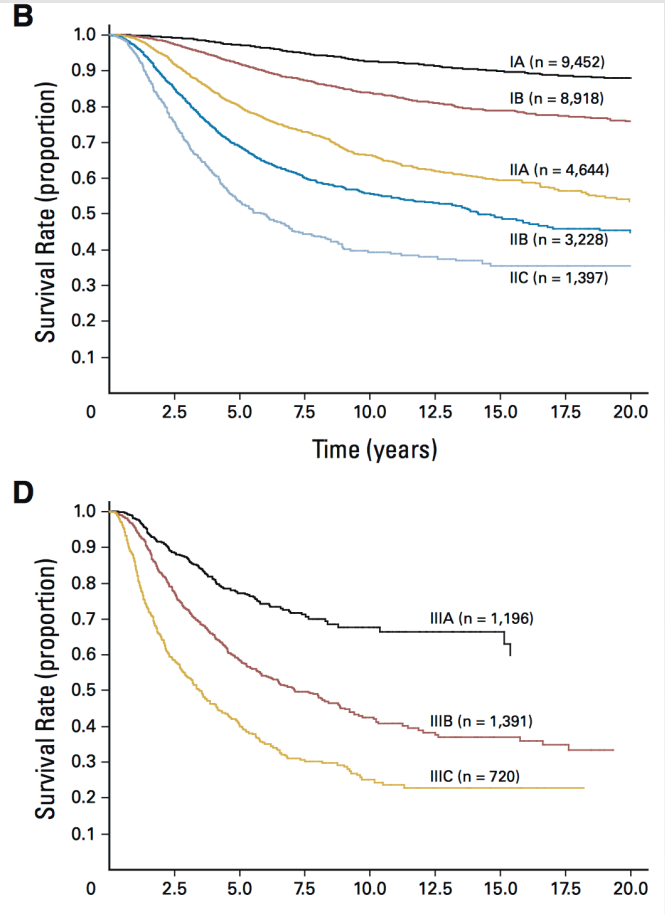

J Clin Oncol. 2009

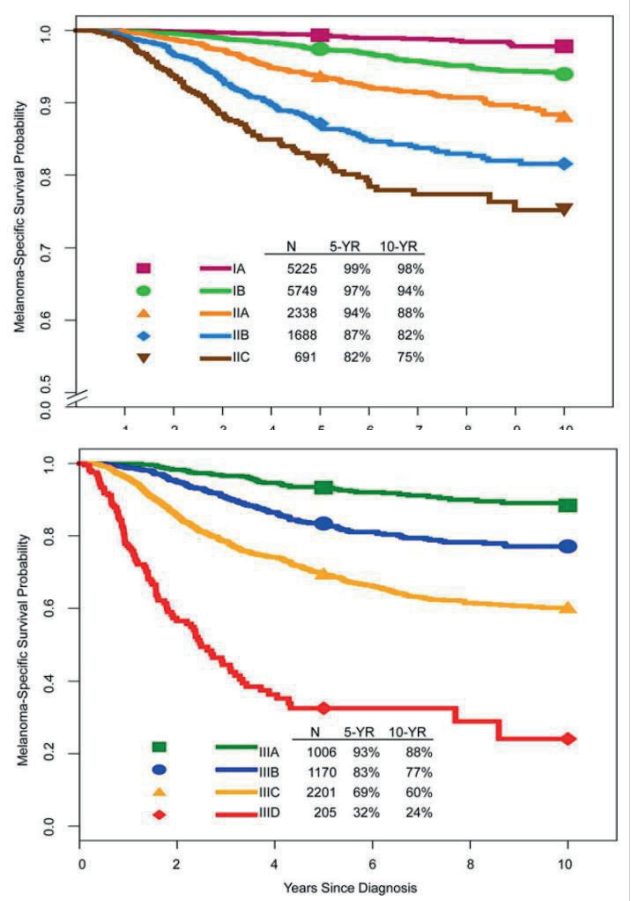

CA Cancer J Clin. 2017 Oct

The NEW ENGLAND JOURNAL of MEDICINE

ESTABLISHED IN 1812 SEPTEMBER 28, 2006 VOL. 355 NO. 13

Sentinel-Node Biopsy or Nodal Observation in Melanoma

Donald L. Morton, M.D., John F. Thompson, M.D., Alistair J. Cochran, M.D., Nicola Mozzillo, M.D., Robert Elashoff, Ph.D., Richard Essner, M.D., Omgo E. Nieweg, M.D., Ph.D., Daniel F. Roses, M.D., Harald J. Hoekstra, M.D., Ph.D., Constantine P. Karakousis, M.D., Ph.D., Douglas S. Reintgen, M.D., Brendon J. Coventry, M.D., Edwin C. Glass, M.D., and He-Jing Wang, M.D., for the MSLT Group*

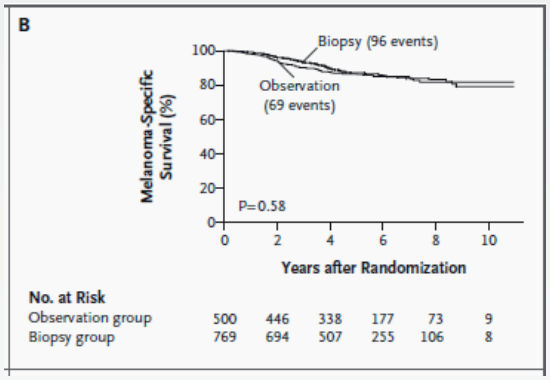

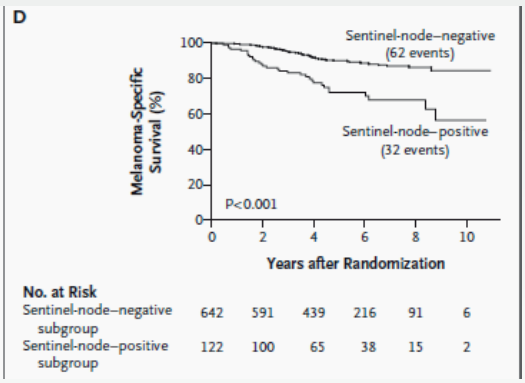

Regional disease Management

The NEW ENGLAND JOURNAL of MEDICINE

ESTABLISHED IN 1812 JUNE 8, 2017 VOL. 376 NO. 23

Completion Dissection or Observation for Sentinel-Node Metastasis in Melanoma

M.B. Faries, J.F. Thompson, A.J. Cochran, R.H. Andtbacka, N. Mozzillo, J.S. Zager, T. Jahkola, T.L. Bowles, A. Testori, P.D. Beitsch, H.J. Hoekstra, M. Moncrieff, C. Ingvar, M.W.J.M. Wouters, M.S. Sabel, E.A. Levine, D. Agnese, M. Henderson, R. Dummer, C.R. Rossi, R.I. Neves, S.D. Trocha, F. Wright, D.R. Byrd, M. Matter, E. Hsueh, A. MacKenzie-Ross, D.B. Johnson, P. Terheyden, A.C. Berger, T.L. Huston, J.D. Wayne, B.M. Smithers, H.B. Neuman, S. Schneebaum, J.E. Gershenwald, C.E. Ariyan, D.C. Desai, L. Jacobs, K.M. McMasters, A. Gesierich, P. Hersey, S.D. Bines, J.M. Kane, R.J. Barth, G. McKinnon, J.M. Farma, E. Schultz, S. Vidal-Sicart, R.A. Hoefer, J.M. Lewis, R. Scheri, M.C. Kelley, O.E. Nieweg, R.D. Noyes, D.S.B. Hoon, H.-J. Wang, D.A. Elashoff, and R.M. Elashoff

http://www.nejm.org/doi/full/10.1056/NEJMoa1613210

Regional disease Management

The NEW ENGLAND JOURNAL of MEDICINE

ESTABLISHED IN 1812 JUNE 8, 2017 VOL. 376 NO. 23

Completion Dissection or Observation for Sentinel-Node Metastasis in Melanoma

M.B. Faries, J.F. Thompson, A.J. Cochran, R.H. Andtbacka, N. Mozzillo, J.S. Zager, T. Jahkola, T.L. Bowles, A. Testori, P.D. Beitsch, H.J. Hoekstra, M. Moncrieff, C. Ingvar, M.W.J.M. Wouters, M.S. Sabel, E.A. Levine, D. Agnese, M. Henderson, R. Dummer, C.R. Rossi, R.I. Neves, S.D. Trocha, F. Wright, D.R. Byrd, M. Matter, E. Hsueh, A. MacKenzie-Ross, D.B. Johnson, P. Terheyden, A.C. Berger, T.L. Huston, J.D. Wayne, B.M. Smithers, H.B. Neuman, S. Schneebaum, J.E. Gershenwald, C.E. Ariyan, D.C. Desai, L. Jacobs, K.M. McMasters, A. Gesierich, P. Hersey, S.D. Bines, J.M. Kane, R.J. Barth, G. McKinnon, J.M. Farma, E. Schultz, S. Vidal-Sicart, R.A. Hoefer, J.M. Lewis, R. Scheri, M.C. Kelley, O.E. Nieweg, R.D. Noyes, D.S.B. Hoon, H.-J. Wang, D.A. Elashoff, and R.M. Elashoff

- MSLT-2, 63 centers (1939 p). Patients with SLN positive (microscopic) or RT-PCR positive (molecular)
- Randomized in completion lymphnode dissection was compared with observation and nodal ultrasonography (4m/2 y; 6m/3y; 12m/5y). Median follow-up: 43 m

Regional disease Management

The NEW ENGLAND JOURNAL of MEDICINE

ESTABLISHED IN 1812 JUNE 8, 2017 VOL. 376 NO. 23

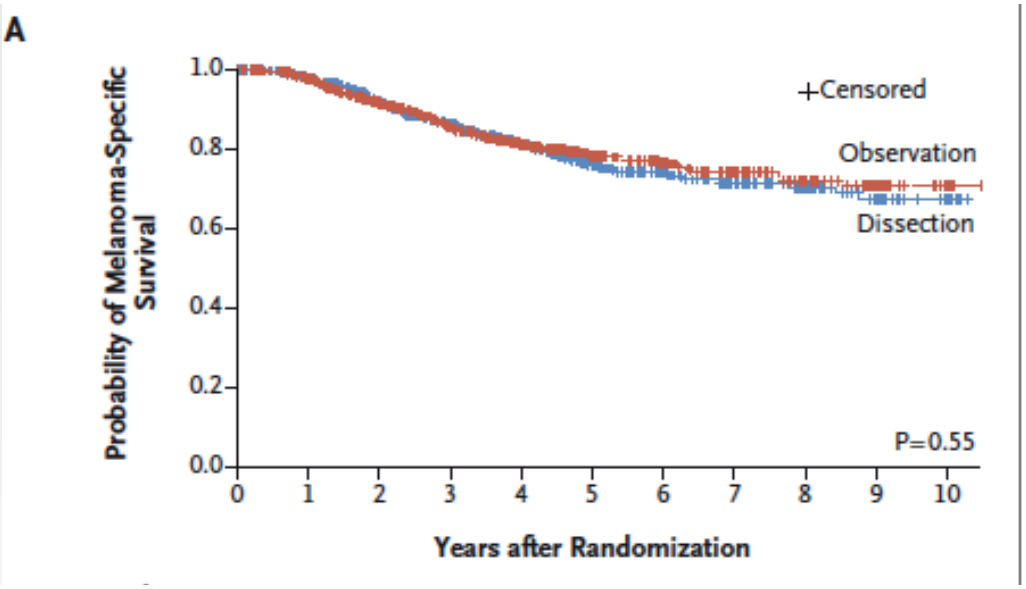

But lymphedema has been observed in 24% of the patients in the dissection group and 6% of the patients in the observation group

Se LN sentinella positivo *(N+clinicamente occulto)*

- .È NECESSARIA LA LINFADENECTOMIA?

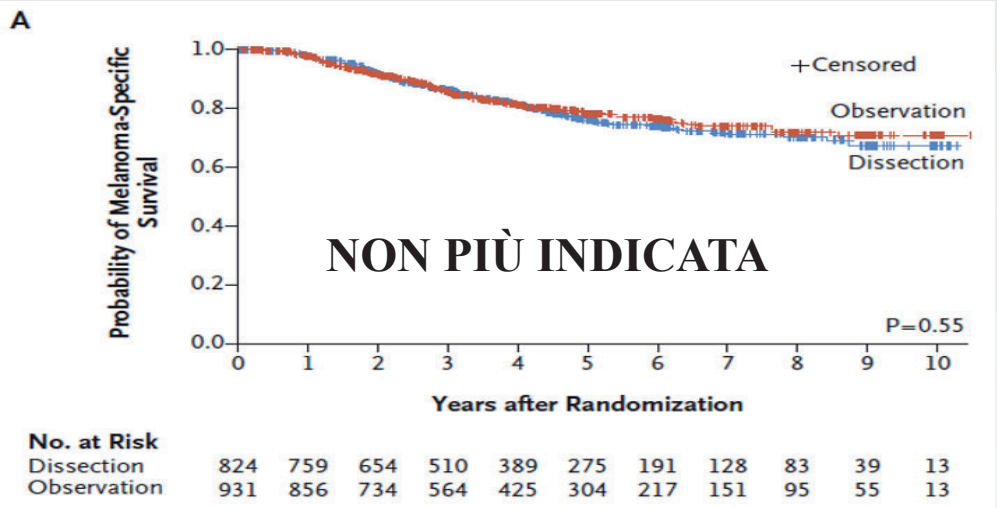

MSLT-II Multicenter Selective Lymphadenectomy Trial

Mark B. Faries N Engl J Med 2017; 376:2211-2222

DECOG-SLT Dermatologic Cooperative Oncology Group

Leiter U et al. Lancet Oncol 2016; 17:757

UTILITÀ BLS

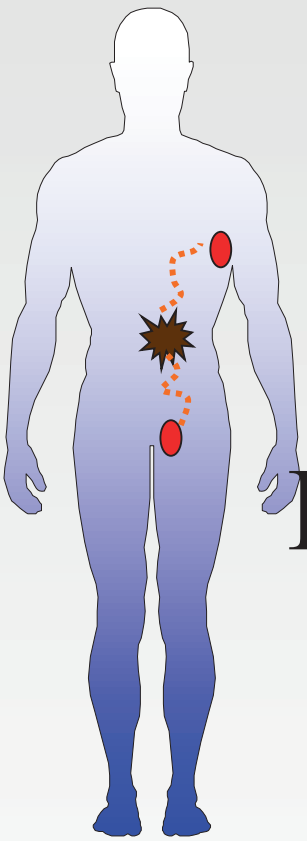

Fattore prognostico

(non terapeutico)

Indicazione a terapia adiuvante

(se metastasi nel LS > 1 mm)

Adjuvant immunotherapy in Melanoma

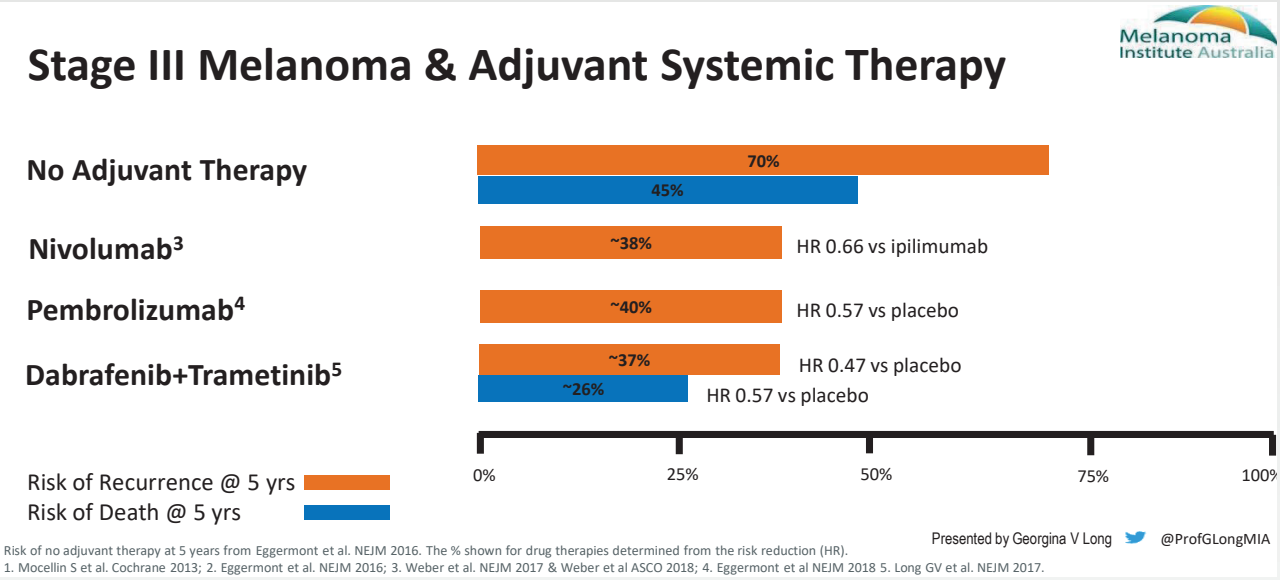

Long, ESMO 2020.

Recommended for stage ≥ IIIB resected melanoma

Pattern of metastasis

Metastasis site	Total	Median time to metastasis, mo	Method of detection: CT	MRI	Laboratory	Physician	Patient	CXR	
Locoregional									
Lymph node*	36	10.7	20*	1*	2*	11	5	-	58%
Skin	29	18.4	-	1	-	17	11	-	3%
Total	65		20	2	2	28	16	-	
Distant metastasis									
Adrenal gland	4	8.1	4	-	-	-	-	-	
Bone	3	14.1	1	-	-	1	1	-	
Brain	10	10.1	-	7	-	-	3	-	
Intestine	1	20.3	-	-	-	-	1	-	
Liver	11	12.3	10	-	1	-	-	-	
Lung	23	20.1	21	-	1	-	-	1	
Pleura	2	37.7	2	-	-	-	-	-	
Spleen	7	11.8	6	-	1	-	-	-	
Total	61	-	44	7	3	1	5	1	83%

Podlipnik, et al. Journal of the American Academy of Dermatology. 2016

Who detects the metastasis?

Performance of diagnostic tests in an intensive follow-up protocol for patients with American Joint Committee on Cancer (AJCC) stage IIB, IIC, and III localized primary melanoma: A prospective cohort study

Sebastian Podlipnik, MD,[a,f] Cristina Carrera, MD, PhD,[a,f] Marcelo Sánchez, MD,[b] Pedro Arguis, MD,[b] Maria L. Olondo, MD,[b] Ramon Vilana, MD,[b] Ramon Rull, MD,[c] Sergi Vidal-Sicart, MD, PhD,[d] Antonio Vilalta, MD,[a] Carles Conill, MD,[e] Josep Malvehy, MD, PhD,[a,f] and Susana Puig, MD, PhD[a,f]
Barcelona, Spain

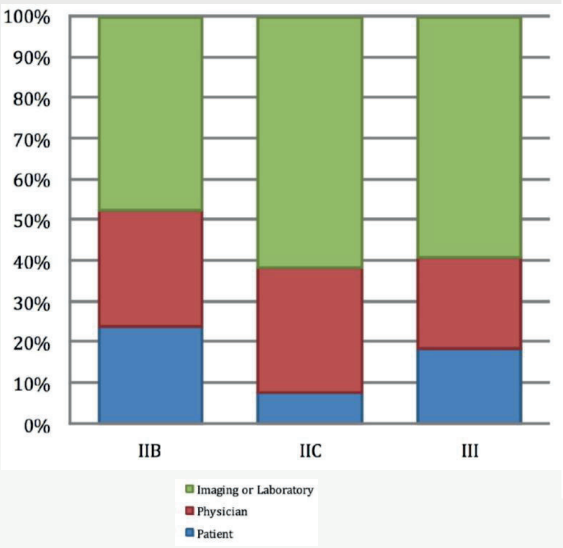

Association between the use of surveillance PET/CT and t detection of potentially salvageable occult recurrences among patients with resected high-risk melanoma

Roberto A. Leon-Ferre[a], Lisa A. Kottschade[a], Matthew S. Block[a], Robert R. McWilliams[a], Roxana S. Dronca[a], Edward T. Creagan[a], Jacob B. Allred[c], Val J. Lowe[b] and Svetomir N. Markovic[a]

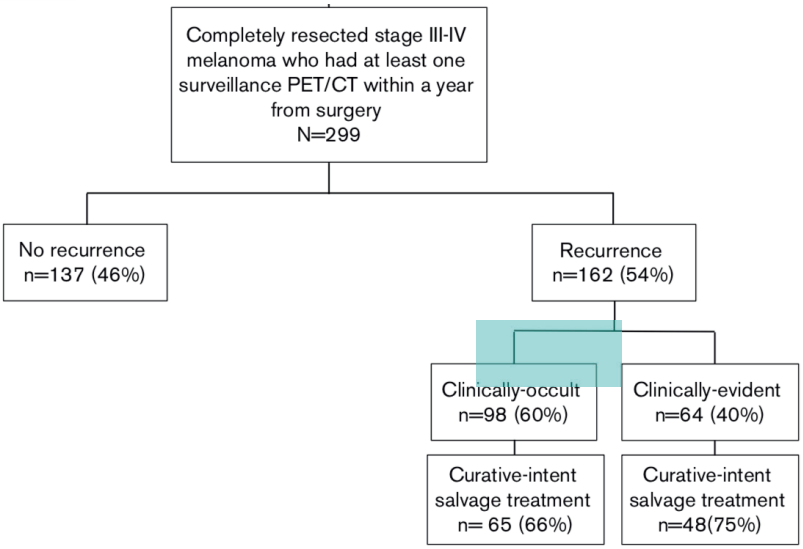

Malattia localmente avanzata o con metastasi in-transito/satellitosi

- Discutere al tumor board se terapia sistemica (vedi malattia metastatica M1) o altre forme di terapia loco-regionale (chirurgia, T-VEC (chiedere CM), RT, imiquimod, elettrochemioterapia)

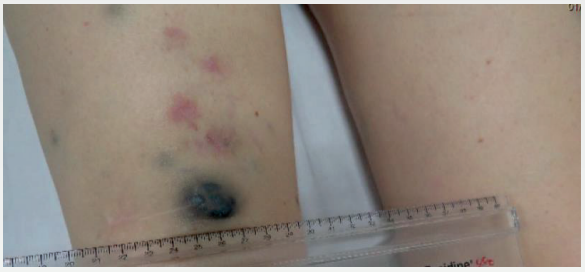

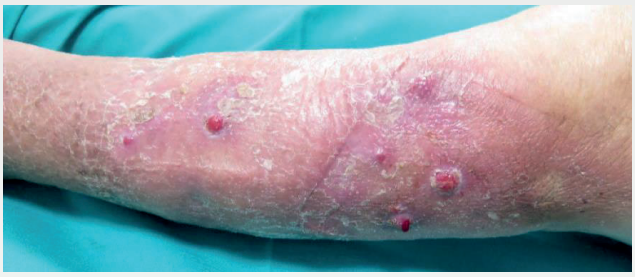

TVEC on MELANOMA STAGE III or IV M1A

FIGURE 1. Talimogene laherparepvec (T-VEC) is a viral oncolytic immunotherapy designed to produce both local and systemic effect resulting in tumor lysis and death.

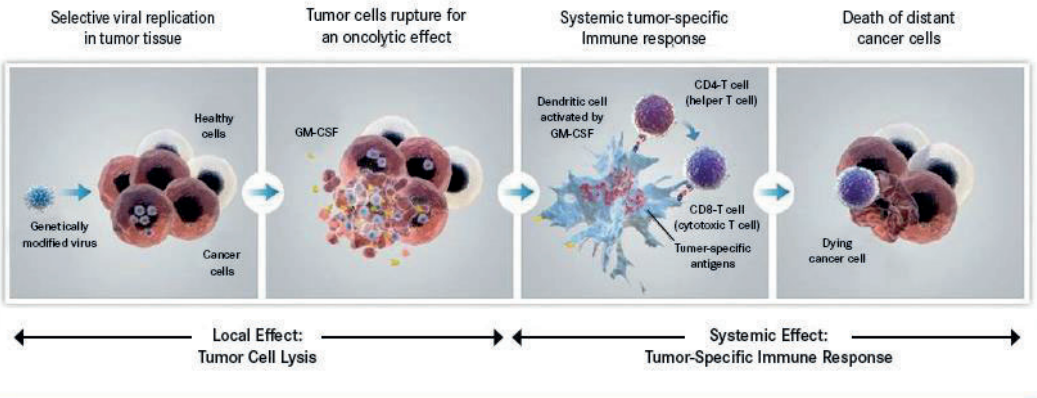

* Reproduced with permission from Amgen.
GM-CSF indicates granulocyte-macrophage colony-stimulating factor.

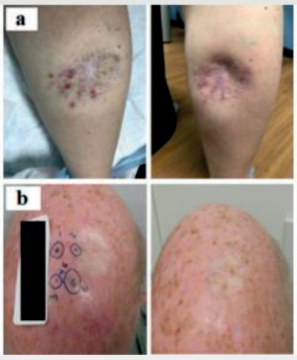

- **(HSV-1) virus with oncolytic properties**
- **The neurovirulence coding sequence is replaced with granulocyte-macrophage colony-stimulating factor (GM-CSF).**
- **Approved for MM stage IIIB-C or IVM1a without bone, lung, CNS or other M1**
- Clinical trails in combination with immunotherapy are ongoing

Perez M. ASO 2018

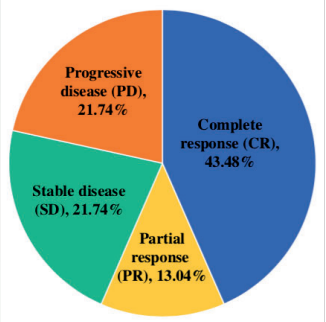

Systemic therapy for Melanoma

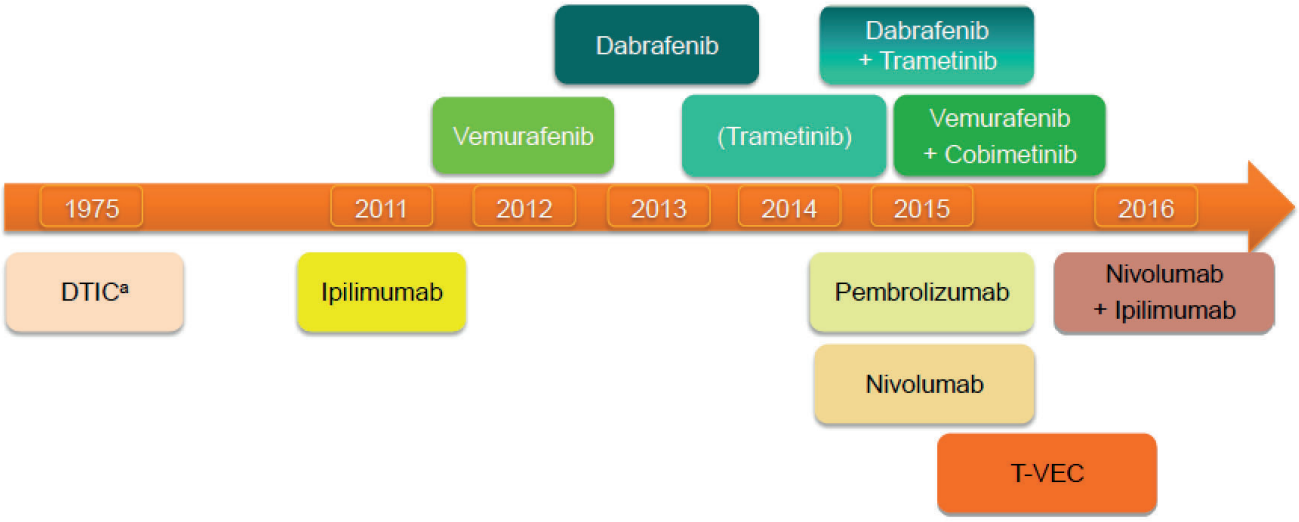


The NEW ENGLAND JOURNAL of MEDICINE
ESTABLISHED IN 1812 AUGUST 19, 2010 VOL. 363 NO. 8

Improved Survival with Ipilimumab in Patients with Metastatic Melanoma


The NEW ENGLAND JOURNAL of MEDICINE
ESTABLISHED IN 1812 JULY 12, 2012 VOL. 367 NO. 2

Improved Survival with MEK Inhibition in BRAF-Mutated Melanoma


The NEW ENGLAND JOURNAL of MEDICINE
ORIGINAL ARTICLE

Nivolumab in Previously Untreated Melanoma without *BRAF* Mutation

The NEW ENGLAND JOURNAL of MEDICINE
ORIGINAL ARTICLE

Pembrolizumab versus Ipilimumab in Advanced Melanoma

The NEW ENGLAND JOURNAL of MEDICINE
ORIGINAL ARTICLE

Improved Overall Survival in Melanoma with Combined Dabrafenib and Trametinib

The NEW ENGLAND JOURNAL of MEDICINE
ORIGINAL ARTICLE

Combined Nivolumab and Ipilimumab r Monotherapy in Untreated Melanoma